

Multiple widespread epidermal cysts of the skin: an unusual presentation

Mehmet Eren Yuksel¹, Funda Tamer²✉

Received: 18 February 2016 | Returned for modification: 17 April 2016 | Accepted: 27 April 2016

To the Editor:

A 31-year-old male patient presented with multiple subcutaneous masses for further clinical evaluation. He stated that the lesions first appeared on both legs and that they had gradually increased in size and number over the previous six years. A physical examination revealed multiple skin-colored subcutaneous nodules on the left zygomatic area, back, chest, dorsum of the right arm, forearm, right little finger, right thigh, and both legs (Figs. 1–2). His past medical history was unremarkable. There was no history of trauma, surgery, or drug injection. None of his family members had similar lesions. However, the patient admitted that his father had died of hepatocellular carcinoma at age 42. His complete blood count was within normal limits. The chemistry panel was within normal limits except for high levels of alanine transaminase and gamma-glutamyl transferase (65 μ /l and 72 μ /l; the reference ranges were 5 to 55 μ /l and 9 to 64 μ /l, respectively). Six of the more prominent lesions were surgically removed because of cosmetic concerns. The patient did well postoperatively. The histopathological examination revealed multiple epidermal cysts with a minimum size of 1.5 \times 1 \times 0.7 cm and a maximum size of 6 \times 3.5 \times 2.5 cm.

Epidermal cysts are common, benign, spherical cutaneous lesions that usually present in hair-bearing areas such as the scalp, face, neck, and trunk. It has been suggested that epidermal cysts occur due to invagination of epidermis into the dermis as a result of trauma. They are usually small and asymptomatic. However, cysts greater than 5 cm are classified as giant epidermal cysts. Giant epidermal cysts are rare and they may lead to cosmetic concerns or pain due to pressure on surrounding structures. These cysts are more likely to rupture and become infected. Furthermore, malignant transformation of giant epidermal cysts has been reported (1). Subcutaneous tumors such as lipomas, neurofibromas, and hemangiomas should be included in the differential diagnosis. Ultrasonography, computed tomography, and magnetic resonance imaging may be helpful; however, histopathological examination is mandatory to reach a definitive diagnosis (2).

Multiple epidermal cysts may be associated with Gardner syndrome, which is an autosomal dominant disease characterized by cutaneous lesions, osteomas, and intestinal polyposis. Moreover, Won et al. reported a 6-year-old male patient with Lowe syndrome and multiple epidermal cysts on the scalp. Nevertheless, these lesions were thought to be coincidental (3).

Epidermal cysts can also occur due to administration of cyclosporine and tacrolimus. Ahn et al. reported multiple epidermal cysts varying from 0.5 cm to 3 cm in diameter on the neck and back of a 44-year-old renal transplant recipient receiving tacrolimus (4).

Small epidermal cysts may be removed by a minimal incision

method. However, traditional elliptical excision is the appropriate technique for treatment of large cysts greater than 2 cm in diameter. In addition, Park et al. reported a small incision method using negative pressure suction to excise large epidermal cysts. Incomplete excisions or fragmentation of the lining may lead to infection and recurrence (5). Draining epidermal cysts using an erbium:yttrium aluminum garnet laser has also been reported as an effective treatment option with good cosmetic results (6). We recently explained the surgical removal of epidermal inclusion cysts with the squeeze technique in detail, which minimizes the risk of wound infection, recurrence, and scar formation (7).

Epidermal cysts may be multiple, but they are usually localized. The patient we presented above had multiple, widespread epidermal cysts on his face, trunk, right little finger, arms, and legs.

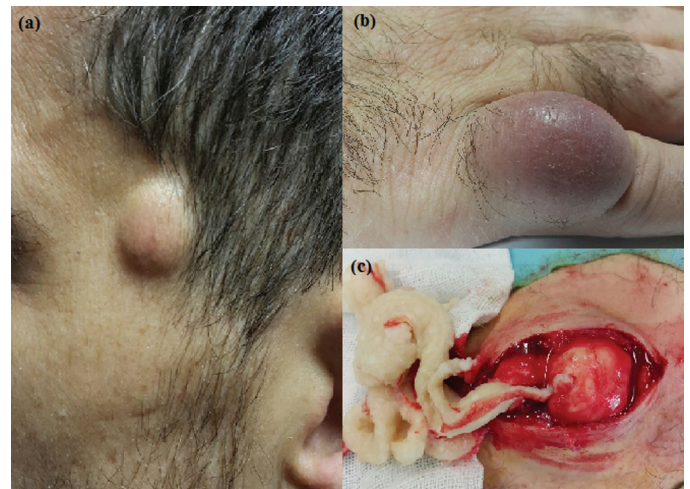


Figure 1 | (a, b) Epidermal cysts on the left zygomatic area and right little finger, (c) Keratinous content protruding through the capsule of the cyst.

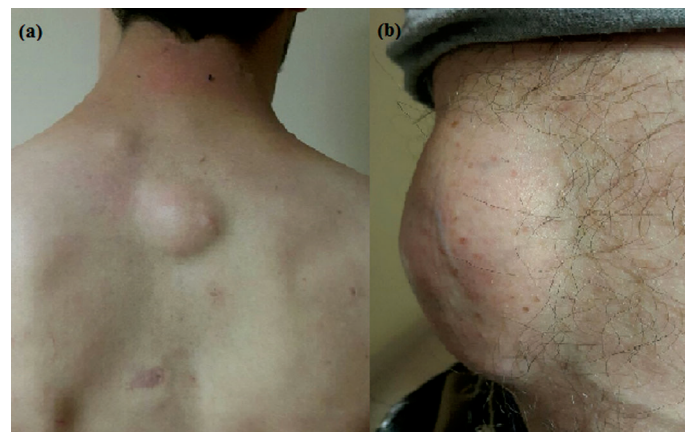

Figure 2 | (a) Multiple epidermal cysts on the back, (b) Giant epidermal cyst on the right leg, 6 \times 3.5 \times 2.5 cm.

To the best of our knowledge, this is the first report of multiple widespread epidermal cysts of the skin ranging from 1.5 to 6 cm.

Therefore, we wished to share this unusual presentation with our colleagues.

References

1. Park TW, Kim JK, Kim JR. Giant epidermal cyst in the posterior neck developing over 40 years: A case report. *Exp Ther Med.* 2014;7:287-9.
2. Im JT, Park BY. Giant epidermal cyst on posterior scalp. *Arch Plast Surg.* 2013;40:280-2.
3. Won JH, Lee MJ, Park JS, Chung H, Kim JK, Shim JS. Multiple epidermal cysts in Lowe syndrome. *Ann Dermatol.* 2010;22:444-6.
4. Ahn IS, Chung BY, Cho SI, Kim HO, Park CW, Lee CH. Epidermal cysts in a tacrolimus treated renal transplant recipient. *Ann Dermatol.* 2011;23:S182-4.
5. Park SW, Choi J, Lee HS, Kim J. Minimal incision suction-assisted excision of a large epidermal cyst. *Aesthetic Plast Surg.* 2015;39:570-3.
6. Feng CJ, Ma H. Treatment of epidermal cysts with erbium: YAG laser fenestration: an alternative to surgical intervention. *Ann Plast Surg.* 2015;74:589-92.
7. Yuksel ME, Tamer F. Surgical removal of the epidermal inclusion cysts with squeeze technique: case report. *Eur Med Health Pharm J.* 2015;8:6-8.