

## MIDDERMAL ELASTOLYSIS

K. Peris, G.P. Mazzochetti, S. Dietrich and S. Chimenti

### ABSTRACT

Middermal elastolysis (MDE) is an acquired idiopathic non-inflammatory dermatosis, clinically characterized by areas of fine wrinkling of the skin, and histopathologically exhibiting a middermal loss of elastic fibers. We report two cases of idiopathic middermal elastolysis recently observed in our department. After considering the main differential diagnoses, we discuss the etiopathogenetic hypothesis underlying the most appropriate therapies.

### KEY WORDS

*middermal elastolysis, idiopathic*

### INTRODUCTION

Middermal elastolysis (MDE) is characterized by well circumscribed areas of fine wrinkling of the skin which histopathologically exhibit middermal loss of elastic fibers. The first reported case was preceded by a recurrent urticarial eruption, which led Shelley and Wood (1977) to postulate that dermal inflammation may have resulted in specific zonal destruction of elastic tissue (1). The histological examination showed a striking absence of elastic tissue in a band-like region, strictly limited to the middle dermis of the involved area. Subsequently, Brenner et al. described a similar idiopathic loss of middermal elastic tissue leading to wrinkling of the skin and perifollicular protrusion in a 33-year-old, otherwise healthy white woman. However, no clinical or histologic evidence of inflammation was found, leading them to propose the term non-inflammatory dermal elastolysis for this entity (2).

More recently, Brod et al. have pointed out an inflammatory pathogenesis of MDE (3), and Kim and Su have

speculated that sun exposure may be one of the main causative factors (4). It has been proposed that the presence or absence of inflammation may mainly depend on the stage of the skin lesions at the time of presentation.

The authors describe two cases of MDE: the first case a 39-year-old woman who presented with wrinkling of the abdominal skin; the other one a 29-year-old woman with numerous yellowish papules on the chest, back and arms.

### CASE REPORT

Case 1. A 39-year-old woman with widespread areas of fine skin wrinkling occurring mainly on the arms and abdomen was examined. There was no previous history of skin diseases. Results of laboratory examinations, chest x-ray and ECG were normal.

Thyroid function tests revealed no abnormalities. Anti-nuclear antibodies were within the normal range. Biopsy



specimens of two lesions stained with hematoxylin and eosin showed no epidermal abnormalities, but disclosed the complete absence of elastic tissue in foci limited to the middermal region. The reticular dermis appeared normal and no inflammatory cell infiltrate was present. Collagen fibers showed no alteration. Histochemical stain specific for elastic fibers confirmed that the absence of elastic fibers was limited to the mid-dermis (Fig. 1).

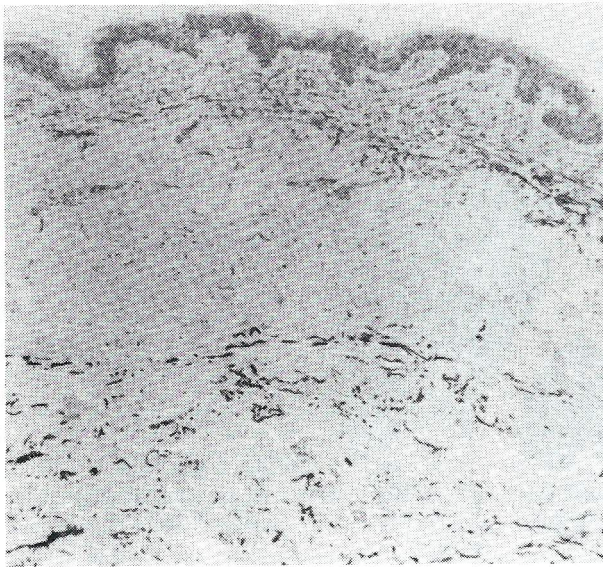


Fig. 1. Histological stain for elastica shows the absence of elastic fibers to the middle dermis (10x)

Case 2. In a 29 year-old woman, numerous, asymptomatic, discrete, yellowish papules, 0.5-0.8 cm in diameter appeared

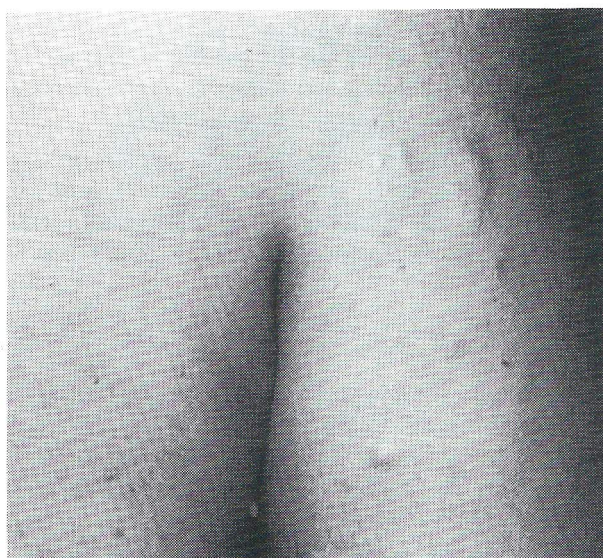

Fig. 2. Clinical aspects of middermal elastolysis

progressively on the upper chest, back, and arms (Fig. 2). There was no previous history of skin disease. Results of laboratory examinations, chest x-ray and ECG were unremarkable. Thyroid function tests disclosed no abnormalities. Antinuclear antibodies were within the normal range. A skin biopsy specimen was obtained from the left arm. Hematoxylin eosin staining demonstrated a normal epidermis and a band-like middermal region with complete loss of elastic fibers. The loss of elastic tissue did not involve perifollicular areas, and the hair follicles were surrounded by well-preserved elastic fibers. A sparse superficial and deep infiltrate of lymphohistiocytic cells was also observed. Collagen fibers displayed no alteration. Histochemical stain with Verhoeff-van Gieson confirmed that the absence of elastic fibers was limited to the mid-dermis.

Patient number 1 was treated according to the literature, using daily application of topical retinoid acid cream of increasing concentration. Patient number 2 was treated with topical retinoic acid cream once daily in conjunction with 70% glycolic acid once weekly. Although a discrete improvement of clinical manifestations was observed in both cases after 6 months of therapy, patient number 2 improved visibly sooner, beginning with the third month of treatment. This earlier improvement presumably resulted from the epidermolytic action of glycolic acid, and suggests enhancing the efficacy of other specific topical therapies (12).

## DISCUSSION

MDE is a rare acquired idiopathic dermatosis that predominantly affects middle-aged women. Lesions frequently involve the arms, trunk and shoulders, while the face is generally spared. Usually, there is no family history or systemic involvement. There are no signs of atrophy or herniation. According to Trueb, the lesions can be classified as localized or generalized, congenital or acquired (5,6). Two morphologic patterns of MDE have been described: type 1 lesions, as in our case 1, appear as tiny wrinkles arranged parallel to the skin cleavage lines. Histology reveals that the elastic tissue is preserved in the superficial dermis but absent in the middle dermis. Generally no inflammatory infiltrate is present.

Type 2 lesions, as in our case 2, appear as small soft papules that consist of perifollicular protrusions. The diffuse loss of elastic tissue in the middle dermis is interrupted by hair follicles surrounded by well-preserved elastic fibers (6).

An inflammatory infiltrate may also be observed. Histologic similarities between anetoderma and type 2 MDE suggest the possibility of a related pathogenesis, so that some authors consider type 2 MDE to be a clinical form of anetoderma (3). MDE should be differentiated from other disorders of acquired elastolysis. In fact, solar elastosis differs



from MDE by its onset in older patients and involvement of sun-exposed areas, by hyperplasia, abnormalities of elastic fibers, and by basophilic degeneration of the collagen in the papillary dermis (4).

Anetoderma is characterized by the absence of widespread wrinkling, and by the presence of herniation as well as elastolytic features involving the entire dermis (7). Cutis laxa differs from MDE by the presence of lax pendulous skin, and the frequent involvement of internal organs (8). Postinflammatory elastolysis and cutis laxa differ from MDE by their occurrence in African women, by the occurrence of preceding urticaria and/or papuloplaques, and by the presence of atrophy and severe disfigurement (9).

The etiology of MDE is poorly understood. Immune reactions, defects in synthesis of elastic tissue, and the release

of elastase by inflammatory cells have all been postulated as possible mechanisms (4). Some authors have also hypothesized that sun exposure could be a contributing factor in the genesis of this disorder. However, the extensive involvement of sun-protected areas and the absence of histological evidence of solar elastosis are not consistent with the latter view that the damage to elastin in MDE results from sun-exposure (3,4). Recently, Fimiani et al. have shown that ultra-violet A (UV-A) stimulation of fibroblasts from two patients with MDE does not change the quantity of elastolytic enzymes, but increases the level of these enzymes in fibroblasts from healthy subjects (10). Lacking a well-understood pathophysiologic genesis for MDE, therapeutic measures are of an empiric nature. At this moment, the most promising treatment consists of topical retinoic acid cream in conjunction with the use of sunscreens (11).

---

## REFERENCES

1. Shelley WB, Wood MG. Wrinkles due to idiopathic loss of middermal elastic tissue. *Br J Dermatol* 1977; 97: 441-445
2. Brenner W, Gschnait F, Konrad K, Holubar K, Tappeiner J. Non-inflammatory dermal elastolysis. *Br J Dermatol* 1978; 99: 335-338
3. Brod BA, Rabkin M, Rhodes AR, Jegasoty BV. Middermal elastolysis with inflammation. *J Am Acad Dermatol* 1992; 26: 882-884
4. Kim JM, Su WPD. Middermal elastolysis with wrinkling: report of two cases and review of the literature. *J Am Acad Dermatol* 1992; 26: 169-173
5. Trueb RM, Burg G. Idiopathic middermal elastolysis. *Dermatol* 1993; 187:62-66
6. Maghraoui S, Grossin M, Crickx B, Blanchet P, Belaich S. Middermal elastolysis: report of case with a predominant perifollicular pattern. *J Am Acad Dermatol* 1992; 26: 490-492
7. Cerroni L, Orlando GC, Peris K, Lunghi F, Chimenti S. Anetoderma di Schweningen-Buzzi *Giorn Int Derm Ped* 1990; 1: 23-29
8. Harris RB, Heaphy MR, Perry HO. Generalized elastolysis (cutis laxa). *Am J Med* 1978; 65: 815-822
9. Lewis PG, Hood AF, Barnett NK et al. Postinflammatory elastolysis and cutis laxa. *J Am Acad Dermatol* 1990; 22: 40-48
10. Fimiani M, Mazzatenta C, Rubegna P, Lungarella G. Middermal elastolysis: Aspetti ultrastrutturali e ruolo delle proteasi elastolitiche. In *Riassunti 69° Congresso SIDEV Sorrento*, 1994
11. Rae V, Falanga V. Wrinkling due to middermal elastolysis. *Arch Dermatol* 1989; 125: 950-951
12. Van Scott EJ, Yu RJ. Alpha hydroxyacids: therapeutic potential. *Canadian J Dermatol* 1989; 1: 108-112

## AUTHORS' ADDRESSES

Ketty Peris MD, Department of Dermatology, University of L'Aquila, Via Vetoio-Coppito 2, 67100 L'Aquila, Italy  
Claudia Cotellessa MD, same address  
Giampero Mazzocchetti MD, same address  
Sergio Chimenti MD, Professor and Chairman of the Department of Dermatology, University of L'Aquila, same address