

A CASE OF BULLOUS SCABIES

C. Veller-Fornasa, M. Tarantello, G. Biasinutto and A. Peserico

SUMMARY

There are several descriptions in the literature of atypical clinical manifestations of scabies and there have been rare reports of pemphigoid-like bullous scabies. This case report describes a 78-year-old male who had been treated 6 months earlier for scabies and who came under our observation due to the onset of erythematous-bullous lesions on his legs and soles. The patient complained of severe pruritus and presented lesions due to scratching on his trunk and back, and isolated burrows on his palms and soles. Routine biochemical and immunologic tests revealed only an increase in total serum IgE. Histological examination performed on a bullous lesion showed detachment of the epidermis at the dermo-epidermal interface and a perivascular infiltrate rich in eosinophils. Direct and indirect immunofluorescence tests were negative. Scraping tests for mites performed on plantar and on the palmar lesions were positive for scabies. A diagnosis of bullous scabies was consequently made and topical treatment with classic acaricides was implemented, leading to complete remission within 15 days.

This case seems worth to be noted because of the rarity of the clinical features and because of the strong resistance of skin lesions to conventional topical therapy.

KEY WORDS

scabies, bullous, pemphigoid-like

INTRODUCTION

There are several reports in the literature of atypical clinical manifestations of *Sarcoptes scabiei* infestation suggestive of contact dermatitis, Darier's disease, dermatitis herpetiformis, urticaria (1), impetigo, tinea, folliculitis, psoriasis, pityriasis rosea, syphilis, xanthoma, histiocytosis, lymphomas, or insect bites (2). To our knowledge, reports on scabies with

bullous pemphigoid-like manifestations are rare (1-7). This report describes a case of bullous scabies that recently came under our observation.

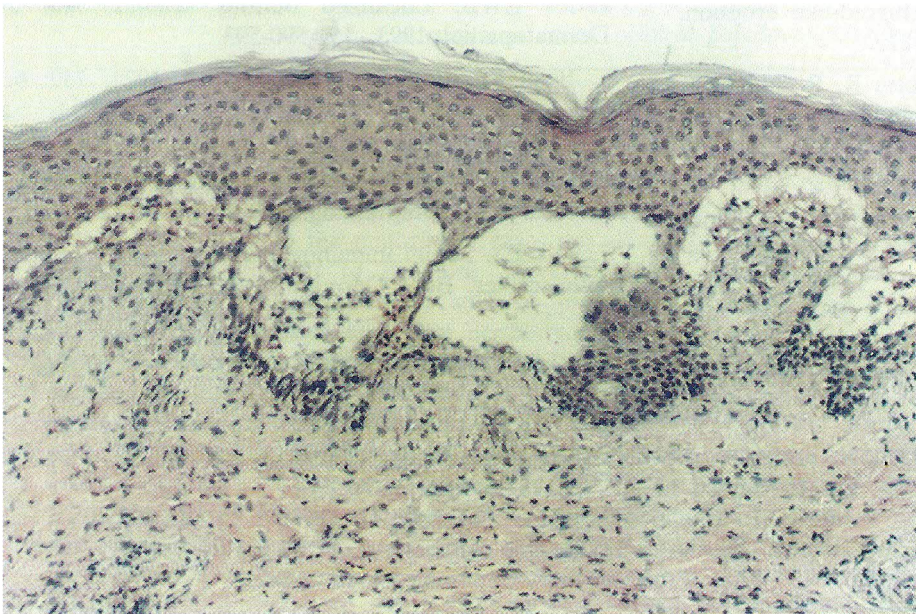
CASE REPORT

A 78-year old male in fair general health came under our observation due to the onset of erythematous bullous lesions containing blood and

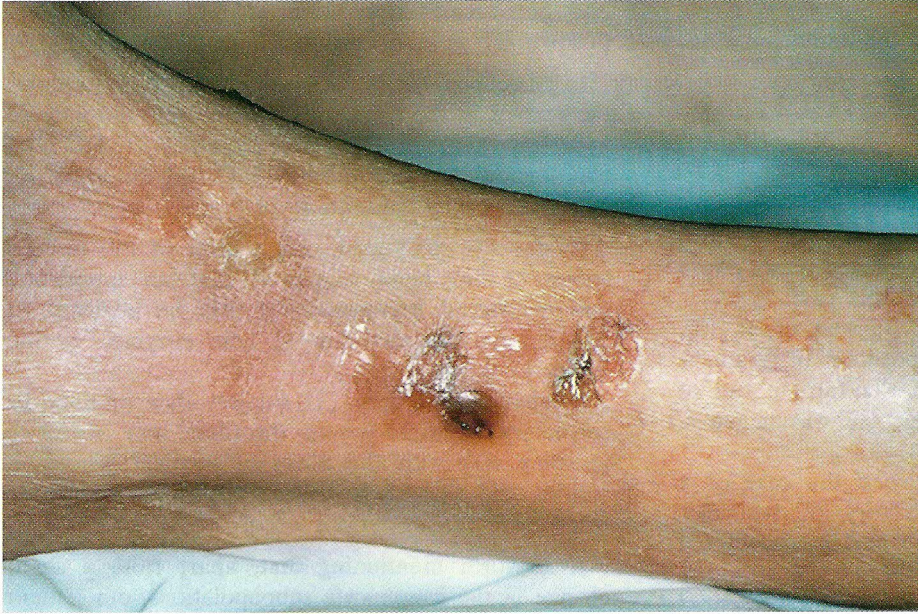

Fig. 1. Clinical aspect: erythematous bullous lesions on the leg.

Fig. 2. Histopathology: detachment of the epidermis at the dermo-epidermal interface and a perivascular infiltrate rich in eosinophils.



serum on his legs and soles (Fig. 1). The patient also presented signs of scratching on his trunk and back and isolated burrows on his palms and soles. He reported having been treated with various types of topical medication for scabies about 6 months previously, without achieving a complete regression of the pruritus.

The biochemical and immunological tests demonstrated an increase in total serum IgE to 562 kU/L (normal range < 200 kU/L). Lymphocyte subpopulation typing revealed an increase in CD3 T lymphocytes to 88.6% (normal range 61-85%) and in CD8 (T suppressor-cytotoxic) lymphocytes to 46% (normal range 14-42%), and a drop in B activated (HLA-DR) lymphocytes to 7.6% (normal range 8-28%) and in B lymphocytes (CD 20) to 0.6% (normal range 3-18%).

Histological examination of a biopsy from a bullous lesion on the leg showed detachment of the epidermis at the dermo-epidermal interface. Numerous neutrophilic and eosinophilic leukocytes were found in the bullous lesion and in the underlying dermis. There was a considerable perivascular infiltrate, particularly rich in eosinophils (Fig. 2). Direct and indirect immunofluorescence tests (DIF and IIF) were negative.

The presence of mites was verified by taking scrapings from the bullous lesions on the soles and palms. The diagnosis of bullous scabies was thus confirmed and treatment was implemented with conventional topical acaricide medication (benzyl

benzoate 25% for 8 days and sulfur for 6 days), which led to the remission of the bullous lesions within 15 days.

DISCUSSION

To our knowledge, there are very few reports of bullous eruptions in scabies (1-6) and the clinical and histological signs in all reported cases were comparable with the findings in this case.

In the 2 cases described by Bhawan et al. (2), DIF proved positive, with deposition of granular IgG in the basal membrane in the former and of linear IgG and C3 in the latter; IIF was negative, however.

Viraben and Dupre (3) described the case of a 34-year old patient with a history of recurrent sinusitis and pneumonia (that the authors considered a sign of immune deficiency) and of atypical dermatitis until puberty. Like our case, this patient presented eosinophilia and raised total serum IgE. DIF and IIF were negative.

In 1993 Said et al. (4) described a case of localized bullous scabies with negative DIF and IIF findings. Ostlere (1), on the other hand, presented a case with both positive DIF findings (a linear band of C3 along the dermo-epidermal interface

and perivascular deposition of IgM and C3) and positive IIF results (anti basal membrane 1:10).

In percentage varying according to different authors, the reports in the literature mention both an increase in serum levels of IgE and deposits of IgG and complement at the dermo-epidermal interface in *Sarcoptes scabiei* infestation (8,9).

As for the pathogenic mechanism of the bullous lesion, it has been suggested that an immediate and/or delayed hypersensitivity may be involved, in addition to the secretion of lytic enzymes by the mites (1,3).

Viraben and Dupre (3) suggest that primary or secondary immune system disorders may correlate in some way with the onset of atypical lesions in scabies and that such disorders must be suspected when such manifestations occur.

It is worth mentioning that, apart from a slight change in the lymphocyte subpopulations, our patient presented no sign of immune deficiency and had not been administered immunosuppressants.

Finally, as already stated by other authors, it is worth emphasizing that the bullous form of scabies presented by our patient proved rather resistant to conventional therapy and took a full 15 days to achieve complete remission.

REFERENCE

1. Ostlere LS, Harris D, Rustin MHA. Scabies associated with a bullous pemphigoid-like eruption. *Br J Dermatol* 1993; 128: 217-219.
2. Bhawan J, Milstone E, Malhotra R, Rosenfeld T, Appel M. Scabies presenting as bullous pemphigoid-like eruption. *J Am Acad Dermatol* 1991; 24: 179-181.
3. Viraben R, Dupre A. Scabies mimicking bullous pemphigoid. *J Am Acad Dermatol* 1989; 20: 134-136.
4. Said S, Jay S, Kang J, Liem WH, Jensen JL, Jeffes EWB. Localized bullous scabies. *Am J Dermatopathol* 1993; 15: 590-593.
5. Bean SF. Bullous scabies. *JAMA* 1974; 230: 6: 878.
6. Triller R, De Ribes C, Barbier D, Beltzer-Garely E. When pemphigoid continues to be itchy. *Medical Staff Dermatologie* 1995; 26: 10-13.
7. Falk ES. Serum immunoglobulin values in patients with scabies. *Br J Dermatol* 1981; 105: 667-678.

AUTHORS' ADDRESSES

Cleto Veller Fornasa MD, Ass. professor, Dpt of Dermatovenereology, University of Padova,
Via C. Battisti n. 206, 35128 Padova, Italy
Marco Tarantello MD, same address
Christina Biasinutto MD, same address
Andrea Peserico MD, PhD, Professor and Chairman, same address