

# *Refractory leg ulcers in a patient with 48,XXYY, a rare variant of Klinefelter's syndrome*

S. Läubli, J. Hafner and G. Burg

## SUMMARY

A case of a 17-year old boy with extensive ulcers on both lower legs is presented. Clinical examination showed an unusually tall stature, obesity and eunuchoid habitus. Chromosomal analysis revealed a karyotype of 48,XXYY, a rare variant of Klinefelter's syndrome (47,XXY). After treatment with moist gauze and many recurrences, rapid ulcer healing could be achieved with topical application of Factor XIII. Patients with 48,XXYY seem to be particularly prone to developing extensive leg ulcers. Possible etiologies include chronic venous insufficiency and microvascular disturbances as a consequence of fibrinolytic abnormalities. Differences between Klinefelter's syndrome (47,XXY) and 48,XXYY are discussed.

## KEY WORDS

male, Factor XIII, fibrinolysis, karyotyping, Klinefelter syndrome, leg ulcers, plasminogen activator inhibitor 1, sex chromosome aberrations, venous insufficiency

## Introduction

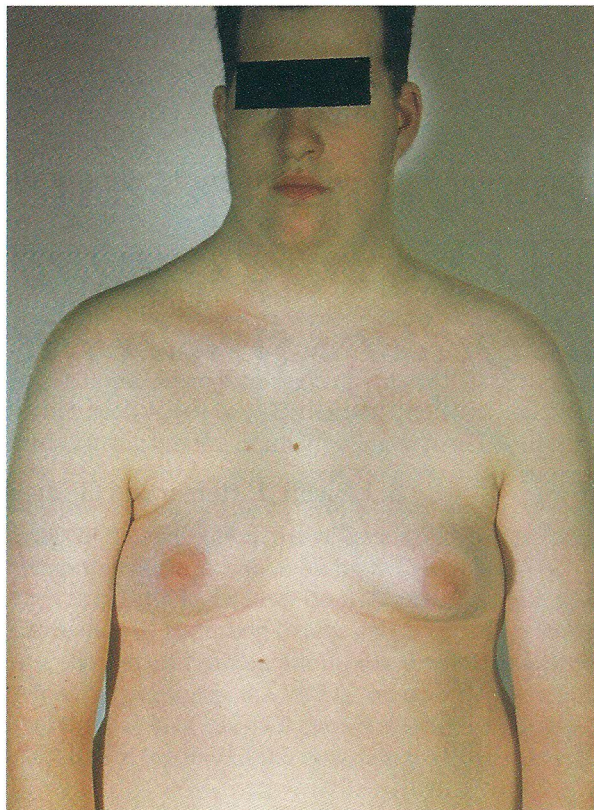
Klinefelter's syndrome is one of the most common chromosomal variations in humans. Patients with this syndrome have at least one extra X chromosome which results in a karyotype of 47,XXY or, in less common variations, 48,XXXYY, 49,XXXXYY and XY/XXY mosaic (1). One rare variant is the 48,XXYY syndrome (2). Boys with the latter syndrome are, like Klinefelter patients, usually of a tall stature with a eunuchoid habitus and small testes. There are, however also some important differences: more often than in Klinefelter syndrome, patients with a 48,XXYY karyotype show cognitive or behavioral problems and extensive ulcers of the lower limbs (3). Patients with a female phenotype and extra X chromosomes can have a karyotype of 47,XXX and usu-

ally show very little, if any, clinical abnormalities, which might include tall stature and neuromotor developmental delay, but normal sexual development.

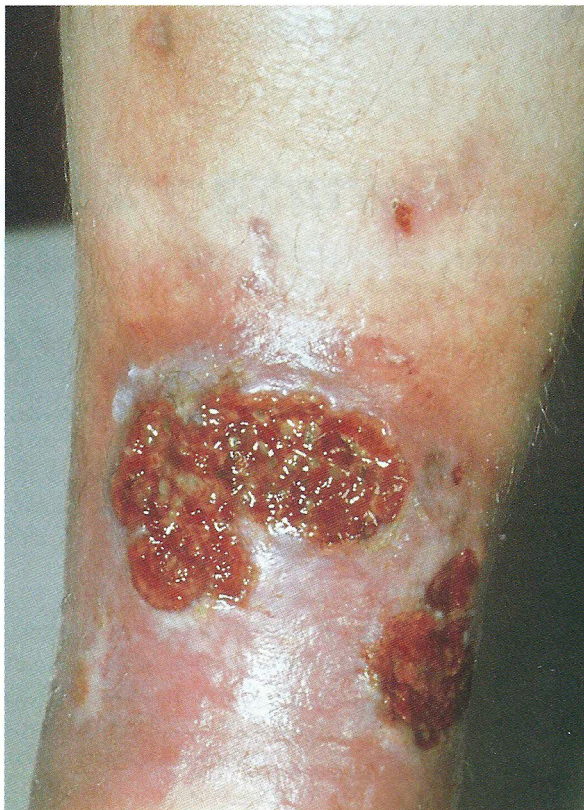## Case report

A 17 year-old boy was seen at our clinic for the first time in 1995 with extensive ulcers on both legs, which had persisted in spite of intensive therapy. His family history was unremarkable for genetic diseases. He had just started an apprenticeship as a cook, a job which involved long periods of standing. Initial examination





**Figure 1.** Patient with XXYY-syndrome featuring tall stature, eunuchoid habitus and gynecomastia



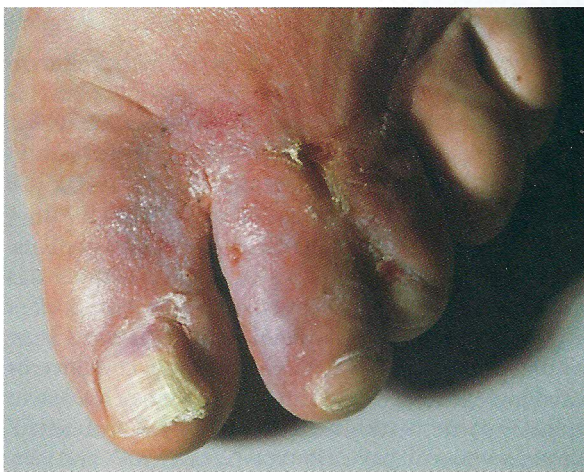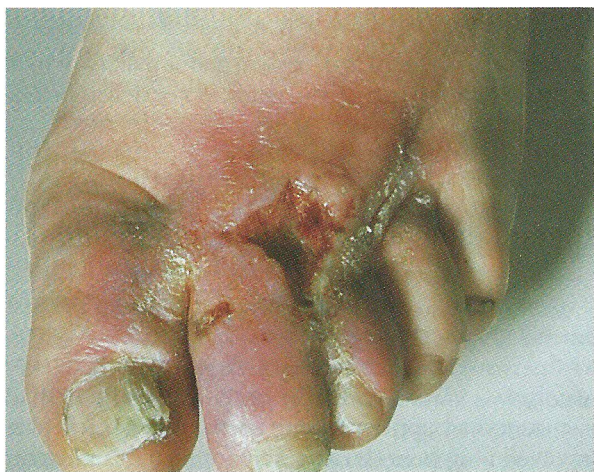**Figure 2.** Heavily exsuding pHeaHHh retibial ulcer of patient with XXYY-syndrome

revealed an unusually tall, obese boy with gynecomastia and hypoplastic testes (Figure 1). Both legs presented with ulcerations on the medial and frontal aspect of the shin (Figure 2) as well as the dorsum of the left foot (Figure 3a). The ulcerations measured up to 6 cm in diameter and were covered with large quantities of fibrinous exsudate. There were no conspicuous varicose

veins and the dorsal arteries of both feet were easily palpable. Blood work showed normal results. In particular, there were no signs of a coagulation disorder, all the parameters including thrombocytes, antithrombin III, Plasminogen, Protein C and S were all within the normal range.

The patient was treated in our outpatient clinic with

**Figures 3 a and b.** Ulcer of the left forefoot before and after treatment with topical Factor XIII





compression therapy and moist gauze dressing, which resulted in complete healing after several months, only to recur a few weeks later. In the following year, insufficiency of both greater saphenous veins could be detected by means of duplex sonography. After stripping of both greater saphenous veins, the ulcers healed for more than one year, but several recurrences followed. In 2001, the patient was readmitted to our clinic with ulcers that had persisted for more than one year. This time, almost complete healing could be achieved within two months with application of topical factor XIII (Fibrogammin  $\hat{a}$ ) in addition to moist, non-adherent wound dressings and compression therapy (Figure 3b).

## Discussion

In the early 1940's, Harry Klinefelter was a traveling fellow at Harvard Medical School in Boston, Mass., where he worked in the endocrinology laboratory. After he broke several pieces of expensive equipment in the laboratory, he was transferred to another department that did not require laboratory work. There, in the group of Dr. Fuller Albright at Massachusetts General Hospital, he had the opportunity to follow a large number of patients. He noticed several unusually tall boys with gynecomastia, small testes and elevated levels of gonadotropin releasing hormone (GnRH) as well as Follicle-Stimulating Hormone (FSH) and lutenizing hormone (LH). This led to the first publication describing this syndrome subsequently named after Harry Klinefelter (4). While it is now generally accepted that the 48,XXYY syndrome is a variant of Klinefelter syndrome, many authors stress the importance of differentiating between the two (3, 5). Both entities can be traced to a common pathogenetic mechanism, i.e. they can be considered a consequence of meiotic non-disjunction during spermatogenesis or oogenesis (2). Because Klinefelter's syndrome is a sexual disorder, its specific features are usually not noticed in individuals until they reach puberty. Boys with Klinefelter's syndrome often show very discrete clinical features, including tall stature, obesity, gynecomastia and eunuchoid habitus, therefore the syndrome is often not diagnosed. These features are shared by patients with all variations of Klinefelter's syndrome. In addition, they have small testes, a normal to low testosterone level and are infertile. Although

claimed by many earlier reports, lower intelligence does not seem to be a consistent feature of Klinefelter's syndrome. However, the prevalence of expressive language disorders seems to be higher amongst patients with Klinefelter's syndrome compared to the average population (6). Some authors claim that patients with 48,XXYY syndrome show more pronounced impairment of cognitive functions than patients with 47,XXY (3, 5). Whilst larger case-series to prove this point are lacking, we cannot confirm this from the experiences with our patient who does not show significant cognitive defects. In comparison to patients with 47,XXY Klinefelter's syndrome, those patients with 48,XXYY have a higher incidence of peripheral vascular abnormalities (3, 5). Varicosities and chronic venous insufficiency are often observed, in Klinefelter patients with a frequency of 11 – 41% (7). Leg ulcers are found in approximately 13% of patients with Klinefelter's syndrome (8). Different theories have been put forward with regards to the etiology of these leg ulcers. One main etiologic factor may be the presence of chronic venous insufficiency. However, ulcers can also be found in patients with Klinefelter's syndrome without venous insufficiency (9, 10). Platelet hyperaggregability has been found to be a contributing factor in two case reports (9, 11). Others have found lower levels of antithrombin III as a consequence of elevated estrogen levels (12). The best documented hypothesis is that these patients have increased plasma activity of plasminogen activator inhibitor 1 (PAI-1) (10, 13, 14) which impairs fibrinolysis, and this may increase tissue hypoxia as well as cell necrosis (15). Treatment of leg ulcers in these patients usually follows the guidelines of modern wound care, mainly employing moist dressings. With these and compression therapy, healing can usually be achieved but the process is often prolonged compared to patients with venous ulcers. In our patient, the best results could be achieved with topical application of coagulation factor XIII (Fibrogammin $\hat{a}$ ). Factor XIII has been shown to regulate fibrinolysis, thereby stabilizing the endothelial barrier function and impeding hyperfibrinolytic activity of matrix-metalloproteinases (16-19). It is especially indicated for heavily exuding ulcers. Clinical studies have shown accelerated healing in venous ulcers (20). Whether leg ulcers in patients with chromosomal anomalies like Klinefelter syndrome or 48,XXYY are a good indication for topical factor XIII has yet to be shown in larger studies.

## REFERENCES

1. Robinson WP, Binkert F, Bernasconi F, Lorda Sanchez I, Werder EA, Schinzel AA. Molecular studies of chromosomal mosaicism: relative frequency of chromosome gain or loss and possible role of cell selection. *American Journal of Human Genetics* 1995; 56(2): 444-51.
2. Waterman DF, London J, Valdmans A, Mann JD. The XXYY chromosome constitution. Deoxyribonucleic acid replication and the Xg blood group. *American Journal of Diseases of Children* (1960) 1966; 111(4): 421-5.

3. Grammatico P, Bottoni U, De\_Sanctis S, Sulli N, Tonanzi T, Onorio AC, et al. A male patient with 48,XXYY syndrome: importance of distinction from Klinefelter's syndrome. *Clinical Genetics* 1990; 38(1): 74-8.
4. Klinefelter HG RE, Albright F. Syndrome characterized by gynecomastia, aspermatogenesis without aleydigism and increased excretion of follicle-stimulating hormone. *Journal of Clinical Endocrinology and Metabolism* 1942.
5. Parker CE, Mavalwala J, Melnyk J, Fish CH. The 48, XXYY syndrome. *The American Journal of Medicine* 1970; 48(6): 777-81.
6. Lucker-Lazerson. Klinefelter syndrome and expressive language disorder. In: *The Even Exchange*; 1997.
7. Becker KL. Clinical and therapeutic experiences with Klinefelter's syndrome. *Fertility and Sterility* 1972;23(8):568-78.
8. Campbell WA, Newton MS, Price WH. Hypostatic leg ulceration and Klinefelter's syndrome. *Journal of Mental Deficiency Research* 1980; 24(2): 115-7.
9. Norris PG, Rivers JK, Machin S, Dowd PM, Griffiths WA. Platelet hyperaggregability in a patient with Klinefelter's syndrome and leg ulcers. *The British Journal of Dermatology* 1987; 117(1): 107-9.
10. Veraart JC, Hamulyak K, Neumann HA, Engelen J. Increased plasma activity of plasminogen activator inhibitor 1 (PAI-1) in two patients with Klinefelter's syndrome complicated by leg ulcers. *The British Journal of Dermatology* 1994; 130(5): 641-4.
11. Higgins EJ, Tidman MJ, Savidge GF, Beard J, MacDonald DM. Platelet hyperaggregability in two patients with Klinefelter's syndrome complicated by leg ulcers. *The British Journal of Dermatology* 1989;120(2): 322.
12. Ramaker J, Goerdts S, Zouboulis CC, Schramm W, Orfanos CE. [Recurrent thrombophlebitis and ulcera crurum as manifestations of hereditary blood coagulation disorders and Klinefelter syndrome. Discussion based on 4 case examples]. *Der Hautarzt; Zeitschrift Fur Dermatologie, Venerologie, und verwandte Gebiete* 1997; 48(9): 634-9.
13. Villemur B, Truche H, Pernod G, De Angelis MP, Beani JC, Halimi S, et al. [Leg ulcer and Klinefelter syndrome]. *Journal Des Maladies Vasculaires* 1995; 20(3): 215-8.
14. Zollner TM, Veraart JC, Wolter M, Hesse S, Villemur B, Wenke A, et al. Leg ulcers in Klinefelter's syndrome-further evidence for an involvement of plasminogen activator inhibitor-1. *The British Journal of Dermatology* 1997; 136(3): 341-4.
15. Margolis DJ, Kruihof EK, Barnard M, Howe K, Lazarus GS. Fibrinolytic abnormalities in two different cutaneous manifestations of venous disease. *Journal of the American Academy of Dermatology* 1996; 34(2 Pt 1): 204-8.
16. Noll T, Wozniak G, McCarson K, Hajimohammad A, Metzner HJ, Inserte J, et al. Effect of factor XIII on endothelial barrier function. *The Journal of Experimental Medicine* 1999; 189(9): 1373-82.
17. Peschen M, Thimm C, Weyl A, Weiss JM, Kurz H, Augustin M, et al. Possible role of coagulation factor XIII in the pathogenesis of venous leg ulcers. *Vasa. Zeitschrift Fur Gefasskrankheiten. Journal For Vascular Diseases* 1998; 27(2): 89-93.
18. Wozniak G, Noll T, Brunner U, Hehrlein FW. Topical treatment of venous ulcer with fibrin stabilizing factor: experimental investigation of effects on vascular permeability. *Vasa. Zeitschrift Fur Gefasskrankheiten. Journal For Vascular Diseases* 1999; 28(3): 160-3.
19. Wozniak G, Noll T. Factor XIII and wound healing. 2002; 22(1): 59-62.
20. Herouy Y, Hellstern MO, Vanscheidt W, Schopf E, Norgauer J. Factor XIII-mediated inhibition of fibrinolysis and venous leg ulcers. *Lancet* 2000; 355(9219): 1970-1.

**A U T H O R S ' A D D R E S S E S** *Severin Läuchli MD, Department of Dermatology, University Hospital, CH-8091 Zürich, Switzerland*  
*Jürg Hafner MD, assistant professor, same address. Corresponding author*  
*Günter Burg MD, Professor and Chairman, same address*  
*Address for correspondence: assistant professor J. Hafner, Department of Dermatology, University Hospital, CH-8091 Zürich, Switzerland*