

## TERBINAFINE IN THE TREATMENT OF TINEA CAPITIS

V. Peharda, M. Kaštelan, L. Čabrijan, M. Saftić and F. Gruber

### ABSTRACT

*Background.* Tinea capitis is a common dermatomycosis in children. A number of systemic and topical agents can be used in treating tinea capitis. Terbinafine is a new allylamine antifungal agent highly effective against dermatophytes.

*Objective.* The efficacy and tolerability of terbinafine in the treatment of tinea capitis in children was studied.

*Methods.* A total of sixteen children with mycologically confirmed fungal infection caused by *Microsporum canis* were enrolled in the study. The patients' age ranged from 6-12 (mean 8.3 years). Patients received 125 mg terbinafine daily for two months.

*Results.* At the end of the trial 14 patients were evaluable: 13 with superficial infection and one case of Kerion. Clinical cure was achieved in 10 (71.4%) and mycological cure in 11 (78.5%) children. The drug was well tolerated with one patient reporting mild gastrointestinal problems.

*Conclusion.* Our results indicate that terbinafine once daily is safe and well tolerated, but not always effective in the treatment of microsporiasis capitis.

### KEY WORDS

*tinea capitis, terbinafine, treatment*

---

### INTRODUCTION

Tinea capitis is a common dermatomycosis in children. During the last few years *Microsporum canis* infections were the most frequent cause of superficial tinea capitis in the Rijeka region. The disease is highly contagious and can be acquired from pets, such as sick cats and dogs as well as from infected persons. It can be also spread among

family members, school children, and infants in day-care centers. The lesions on the scalp are characterized by the formation of one or a few round areas covered with gray scales in which the hair is broken a few millimeters above the skin (1-3).

A number of systemic and topical agents can be used in treating tinea capitis. Some of the conventionally used antifungal drugs may be ineffective or may cause serious side effects. Oral antimycotic

Table 1. Demographic characteristics of the patients treated with terbinafine.

males (%)	10 (62.5)
females (%)	6 (37.5)
age (mean value)	6-12 (8.3)
weight (kg, mean value)	20-42 (25.6)

suitable for pediatric use must be safe with few adverse effects and effective over a short period. Terbinafine is a new allylamine antifungal agent highly effective against dermatophytes (4). It inhibits the biosynthesis of fungal ergosterol by blocking the enzyme squalene epoxidase. Squalene accumulation and decreased cell-membrane sterol synthesis are responsible for the fungicidal effect of terbinafine. We have studied the efficacy and tolerability of terbinafine in the treatment of tinea capitis in children.

## PATIENTS AND METHODS

Sixteen children (10 males and 6 females, aged 6-12 years) with tinea capitis caused by *Microsporum canis* were included in the study. Demographic characteristics of the patients are presented in table 1. Children treated with other antimycotics and with isolation of *Trichophyton sp.* from the lesion were excluded. The diagnosis was based on clinical examination, Wood light, and direct microscopy of scrapings from the lesion with potassium hydroxide

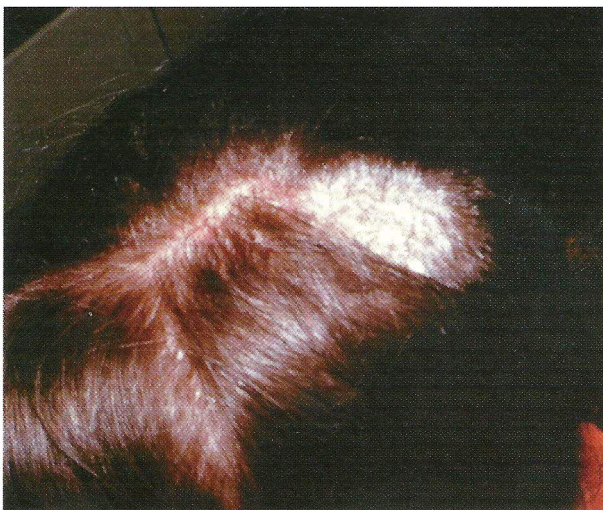

Figure 1. Lesion on the scalp caused by *M.canis*.

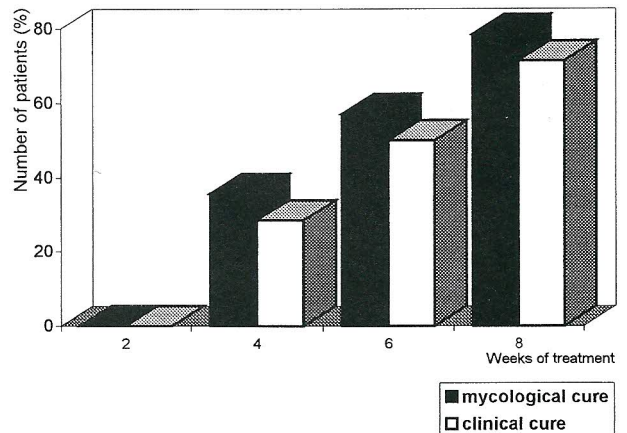


Figure 2. Results of treatment of tinea capitis with terbinafine; clinical and mycological cure.

and later confirmed by culture on Sabouraud's agar. Microscopy and cultures were performed before starting the therapy and then at each visit every two weeks, at the end of treatment and at follow-up one month after finishing the therapy. Clinical signs and symptoms including erythema, scaling, and pruritus were assessed at the initial examination and at each subsequent examination. At the end of therapy and at follow-up, the results were evaluated as clinical and mycological cure (microscopy and culture negative, minimal clinical signs and symptoms). The duration of the disease varied from 3 weeks to 3 months. No underlying disease was present in the enrolled patients. Prior to therapy and at the end, liver function tests were performed. The patients and their parents were questioned for side effects.

All patients received 125 mg/day of terbinafine for 2 months. Therapy was completed within 8 weeks if the patient was cured both mycologically and clinically.

## RESULTS

A total of 16 children with tinea capitis caused by *Microsporum canis* were enrolled in the study; 15 had superficial forms of the disease (Fig.1) and one child had Kerion. At the end of the trial only 14 patients were included in the analysis of terbinafine's efficacy. One child was excluded, being irregular in taking medication, the other had gastrointestinal problems caused by terbinafine.

The mycological and clinical cure rates of analyzed patients are presented in Fig.2. As seen, after 4 weeks of treatment 5 (35.7%) children showed

mycological clearing, while clinical cure was obtained in 4 (28.55%) patients. At week 6 mycological cure was seen in 8 (57.1%) and clinical cure in 7 (50%) children. At the end of trial 11 (78.5%) had negative microscopy and culture, but only 10 (71.4%) patients were completely clinically cured. At follow-up, one month later, the cure rates were the same. The liver function tests were within the normal values before and after the treatment. In only one patient a side effect was observed (gastrointestinal troubles), and one had a slight local irritation.

## DISCUSSION AND CONCLUSION

It is well known that topical antimycotics are not effective in children with tinea capitis. Oral antifungal agents are required. Until recently griseofulvin has been mostly used in treating children with mycoses. It is safe, well tolerated, but only fungistatic, so it has to be taken for a longer period. Problems are also posed by children who do not respond to griseofulvin or have allergic reactions to the drug. Ketoconazole is not acceptable for children due to its hepatotoxicity. There are only limited data on the use of other azoles in children such as fluconazole and itraconazole. The high risk of drug interactions

may further limit their pediatric use. Most experience in treating children with tinea capitis has been obtained with terbinafine. Haroon et al. has studied the efficacy and safety of oral terbinafine in 10 children with dry non-inflammatory tinea capitis caused by *Trichophyton sp.* (5). After 6 weeks of therapy all children showed improvement. Similar results were reported by Nejjam et al. and in a larger study on 100 children by Elewski (7). We have studied the efficacy and tolerability of oral terbinafine in children with tinea capitis caused by *Microsporum canis*. Our results showed mycological cure in 78.5% and clinical cure in 71.4% of patients after completing therapy. One month later the cure rate was the same. The drug was well tolerated but probably caused in one patient abdominal pain and nausea. Still, some patients were not completely cured, but clinical improvement was seen at the end of treatment.

This study indicates that terbinafine is not always effective in treating children with tinea capitis caused by *Microsporum canis*. It is well tolerated but can cause gastrointestinal complaints, and seems to be an appropriate alternative for griseofulvin. However, these are results in a small group of children and more clinical experience is needed.

## REFERENCES

1. Rogers M, Muir D, Pritchard R. Increasing importance of *Trichophyton tonsurans* in childhood tinea in New South Wales. *Austral J Dermatol* 1993; 34: 5-8.
2. Baran E, Szepietowski J, Walow B, Polakiewicz M. Tinea capitis in South-West Poland. *Acta Dermatovenereol Croat* 1994; 2: 29-33.
3. Frieden IJ, Howard R. Tinea capitis: Epidemiology, diagnosis, treatment, and control. *J Am Acad Dermatol* 1994; 31:S 42-6.
4. Gupta AK, Sauder DN, Shear DN. Antifungal agents: An overview. Part II. *J Am Acad Dermatol* 1994; 30: 911-33.
5. Haroon TS, Hussain I, Mahmood A, Nagy AH, Ahmad I, Ozahid I. An open clinical pilot study of the safety of oral terbinafine in dry noninflammatory tinea capitis. *Br J Dermatol* 1992; 126 (suppl 39): 47-59.
6. Nejjam F, Zagula M, Cabiac MD, Guessous N, Humbert H, Lakhdar H. Pilot study of terbinafine in children suffering from tinea capitis: Evaluation of efficacy, safety and pharmacokinetic. *Br J Dermatol* 1995; 132: 98-105.
7. Elewski BE. Cutaneous mycoses in children. *Br J Dermatol* 1996; 134 (suppl 46):7-11.

## AUTHORS' ADDRESSES

Vesna Peharda MD, Department of Dermatology, Clinical Hospital Center, Krešimirova 42, 51000 Rijeka, Croatia.

Marija Kaštelan MD, same address

Leo Čabrijan MD, same address

Marina Saftić MD, same address

Franjo Gruber MD, PhD, professor of dermatology, Head of the Dpt. of Dermatology, same address