

# TROMBIDIOSIS

M. Pogačnik and A. Kansky

## SUMMARY

Trombidiosis is a self-limited, but very annoying disease. After the Second World War the amount of new literature dealing with it, has been decreasing, owing to rising interest in many new diseases.

As trombidiosis may sometimes be important in differential diagnosis in respect to more severe diseases, some less known facts about the vital cycle of chiggers are discussed. The clinical findings and the course of trombidiosis are mentioned. It is not an unusual condition in certain places in the Ljubljana area, specially in early summer.

## KEYWORDS

*larva, trombicula autumnalis, itching dermatitis, review*

## INTRODUCTION

Trombidiosis is a self-limiting disease, appearing mostly during late spring and early summer, but also in autumn. Itching and red macular and papular lesions are the prominent symptoms.

Synonyms: trombidiasis, trombiculiasis, trombiculosis, scrub itch, autumnal itch, erythema autumnale.

## EPIDEMIOLOGY

The so-called "harvest mites" (chiggers, red bugs, or scrub itch mites) belong to the family Trombiculidae

(order Acarinae) (1). They are similar to ticks, but are much smaller. More than 1200 species of Trombiculidae have been described (2) since 1790 when *Trombicula autumnalis* was discovered (3).

Some species of Trombiculidae cause a very irritating dermatitis. *Trombicula autumnalis* is an important chigger in Europe, *T. desaleri*, *T. japonica*, *T. zachvatkini*, *T. toldti*, *Euschoengastia serothermobia* are also known to be parasitic for humans (4).

Others are important vectors of rickettsial diseases (*T. akamushi*, *T. deliensis*, *T. fletcheri*, *T. intermedia*, *T. pallida*, and *T. scutellaris*).

The family is cosmopolitan in distribution, it is



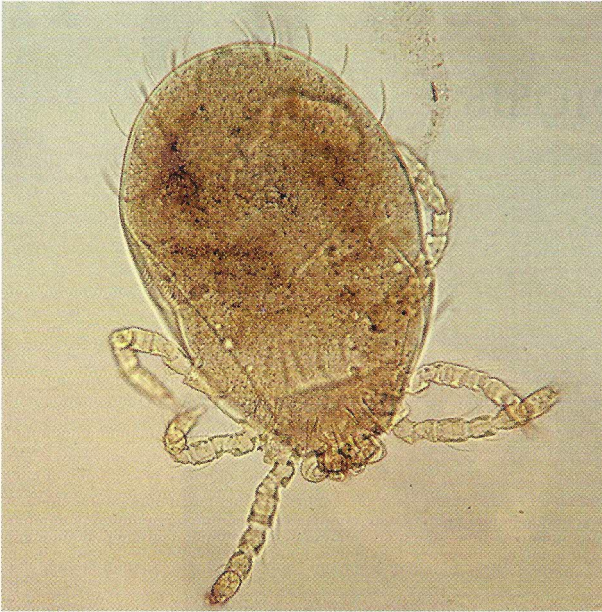


Figure 1. *Trombicula autumnalis*; the larva.

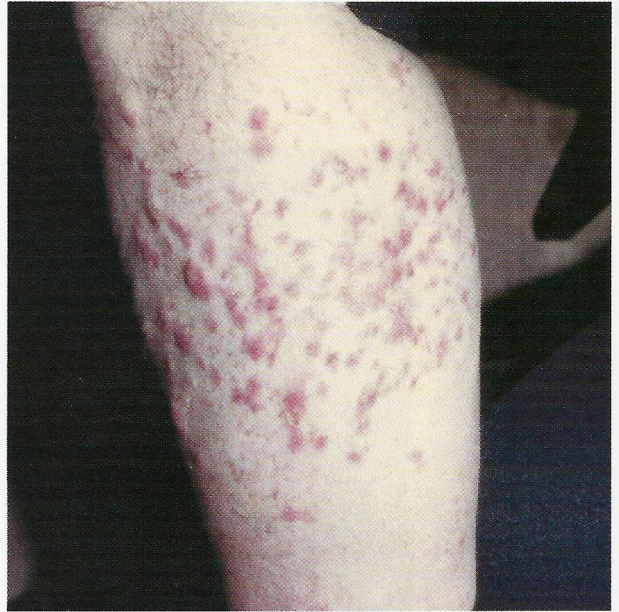

Figure 4. *Trombidiosis*. Macular and papular lesions on the leg.

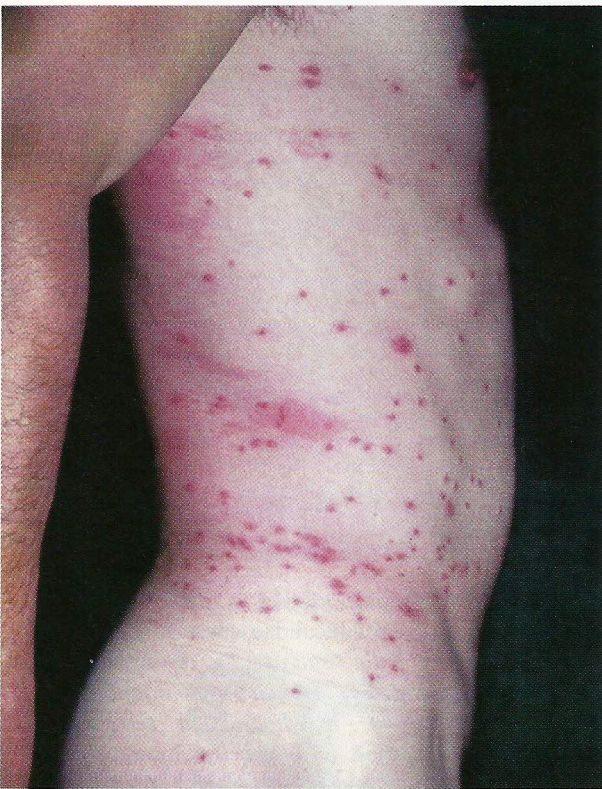

Figure 2. *Trombidiosis* in a male patient: macular and papular lesions concentrated around the belt area.

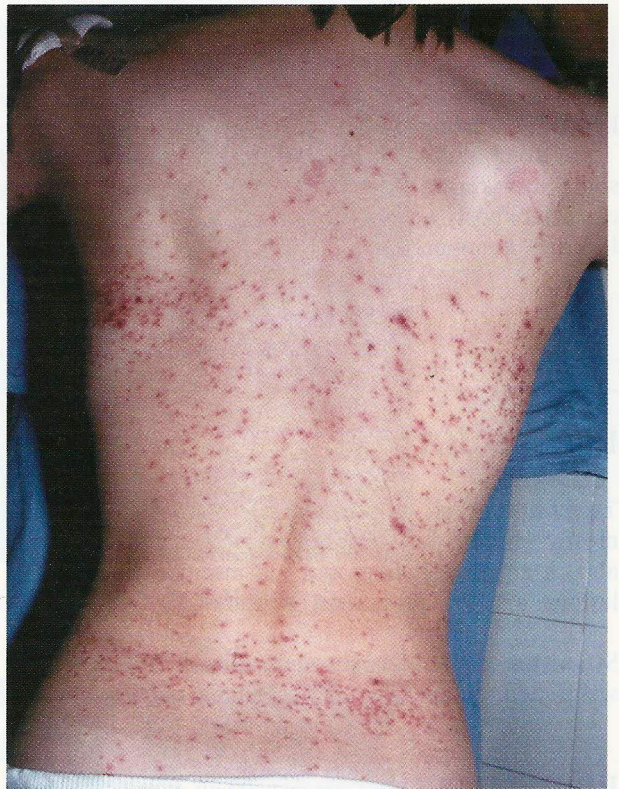

Figure 3. *Trombidiosis* in a female patient: macular and papular lesions expressed mostly around the belt and the bra areas.



prevalent in the tropics and warmer regions, usually appearing in larger numbers during the wet seasons. They may be found at various altitudes ranging from sea level to over 5000 meters in the Andes (5).

There are some older reports on the occurrence of trombidiosis from many parts of Europe. It seems, however, that certain regions are more exposed to the infestation as are surroundings of Vienna or the Tyrol region in Austria or the area around Basel in Switzerland. A number of cases were reported also from other countries like Germany, France, Italy, and the Netherlands (4). It is also known that the prevalence of the mites in any given area may show striking variation from year to year.

According to the data from the Department of Dermatology in Ljubljana, trombidiosis appears in this area at certain localities. The outbreak is usually observed during late spring and early summer, less frequently in autumn. Exposed are mostly children and hikers resting in grass or walking through bushes.

## PARASITOLOGY

They are parasitic as larvae, but free-living as nymphs and adults. The larvae infest vertebrates and may attack human beings or livestock. The larva is 0.25-0.4 mm long, yellow to orange - red in color and has three pairs of legs. The adult parasite is 1-1.5 mm long, red orange and has four pairs of legs (6). Figure 1.

The eggs are laid in soil, but the six-legged larvae climb onto low vegetation to wait for suitable hosts upon which they must feed before again dropping to the ground and molting (7). The larvae mainly attack agricultural workers, but also attack hikers during picnics or walks in the country and even persons at work in the garden (4).

After reaching the host the larvae move to areas, where the skin is thin (5), e.g. around the ankles, axillae, groins, genital region, but some advance along the skin until they are stopped by tight fitting clothing as around belts, braces or bras. Figures 2 and 3. However, other areas of the skin may also be involved (8). Figure 4.

There they pierce the skin with their claws and inject saliva, which has cytolytic properties. The mites feed on tissue fluids and cell debris, according to some authors they also suck blood (9). Such feeding periods are usually short, and feeding on human beings is not very convenient for the future development of larvae.

Only exceptionally the larvae can still be detected on the skin as barely discernible red dots.

## CLINICAL FINDINGS

The patients become as a rule aware of the contact with parasites due to the irritant effect of the mites' saliva, after they have dropped off. The possible acquired hypersensitivity of the host to the salivary antigens is being discussed.

Within a few hours slightly pruritic tiny red macules appear and after 24-48 hours they gradually develop into extremely itching papules or papulo-vesicles, 0.5-2 cm in diameter, often slightly haemorrhagic. Sometimes they could be similar to the lesions seen with fleabites or chicken-pox. In heavy infestation, the whole body is covered with lesions. Children may suffer from such generalized attacks. Seldom regional lymphadenitis and systemic symptoms develop (temperature, lymphocytosis) (10).

The pruritus normally lasts about a week and skin lesions are expressed for up to 2 weeks, but residual pigmentation may last for months.

*Diagnosis* is based on the history, the sudden onset, the locality where the contact took place, the typical season (May to October). The distribution of lesions is of certain help in establishing the diagnosis.

*Differential diagnosis:* prurigo simplex acuta, scabies, urticaria, strophulus infantum, insect bites, Henoch - Schoenlein purpura, leukocytoclastic vasculitis.

## TREATMENT

The treatment is directed at the relief of itching and at the prevention of secondary infections. Topical treatment with zinc lotion or glucocorticoid ointments is recommended, in severe cases also oral antihistamines are used.

It seems that insect repellents are highly effective prophylactic agents.

## CONCLUSION

General practitioners are often not sufficiently familiar with the manifestations of trombidiosis. The condition is tedious because of the severe itch; it is however self-limiting. Diagnostic problems may arise with respect to infectious exanthemas.

## REFERENCES

1. Likar M. Pregled medicinske parazitologije, *Medical Faculty, Ljubljana*, 1974; 151-158.
2. Rook-Wilkinson Ebling. *The Textbook of Dermatology*, Blackwell, Oxford, 1992; 1313.
3. Popović R. Kožne spremembe zaradi klopov ter trombidioza in gamasidioza, *Kogojevi dnevi Zbornik predavanj, Ljubljana, UKC*, 1985; 114-5.
4. Mumcuoglu Y, Ruffli Th. *Dermatologische Entomologie*, Erlangen, *Perimed Fachbuch*, 1983; 158-63.
5. Orlando Canizares. *Clinical Tropical Dermatology*, Blackwell Scientific, Oxford, 1975; 240-241.
6. Naegele A. *Advances in Acarology*, Itchaca, New York, *Cornell University*, 1963; 399-407.
7. Plorde James. *Diseases caused by bites and stings*, In *Harrisons' Principles of internal medicine*, McGraw-Hill Book Company, 1983; 1240.
8. Betetto M and Fettich J. *Mala dermatovenerologija*, Ljubljana, *Mihelač*, 1993; 125.
9. Braun-Falco O, Plewig G. Wolff H. *Dermatologie und Venerologie*, München, *Springer Verlag*, 1995; 333.
10. Altmeyer P, Bacharach-Buhles M. Holzmann H, *Bildlexikon der Dermatologie*, München, *Springer Verlag*, 1994; 914.

## AUTHORS' ADDRESSES

Mihec Pogačnik MD, Dermatologist, Railway Medical Centre, Celovška 4, Ljubljana, Slovenia  
Aleksej Kansky MD, Ph.D., professor of dermatology, Department of Dermatology, UMC, Zaloška 2,  
1525 Ljubljana, Slovenia