

# INTERMITTENT ITRACONAZOLE IN THE TREATMENT OF DISTOLATERAL ONYCHOMYCOSIS - OUR EXPERIENCE

I. Prelog and M. Dolenc-Voljč

## ABSTRACT

*Background.* Itraconazole is a broad-spectrum triazole with known efficacy in pulse therapy for various dermatomycoses.

*Objectives.* To perform an analysis of the efficacy of pulse therapy with itraconazole in treating distolateral toenail and fingernail onychomycosis and to evaluate the safety of intermittent treatment with itraconazole.

*Patients and methods.* The study was completed by 17 patients. Treatment consisted of two pulses of itraconazole, 200 mg twice daily, for seven consecutive days each month for fingernail onychomycosis and of three pulses for toenail onychomycosis. Clinical evaluation was made before treatment, at each month during treatment period and at week 24, 36 and 48 post-treatment. Mycological examinations were performed at the beginning and the end of therapy as well as at each post-treatment visit.

*Results.* Progressive improvement of all clinical signs of onychomycosis was noted at each point of patient evaluations. Mycological cure results were statistically significant comparing pre-treatment status with the final visit at week 48. In two patients with toenail onychomycosis on the last visit relapse was considered.

*Conclusions.* Very satisfactory clinical and mycological responses were observed in our patients. Itraconazole therapy was also associated with good tolerability and patient compliance.

## KEY WORDS

*onychomycosis, itraconazole, pulse therapy*

---

## INTRODUCTION

In the past, onychomycosis has been regarded more as a cosmetic problem and often remained untreated. This was mainly because treatment with traditional antifungal agents required long treatment with disappointing success rates. Relapses were frequent especially in toenail infections which are generally more recalcitrant to treatment than fingernail onychomycosis.

Besides, systemic therapy for onychomycosis represented a high risk of troublesome systemic side effects, which might become significant with prolonged drug use (1,2).

In recent years, the introduction of new oral antifungal agents in the treatment of onychomycosis, especially itraconazole and terbinafine, resulted in improved cure rates with shorter treatment duration, lesser risk of side effects and lower relapse rates

(2,3,4). Both itraconazole and terbinafine have been found to be effective and safe in the therapy of onychomycoses.

Pulse therapy with itraconazole was developed with the aim of maintaining efficacy, reducing costs, improving patient's compliance and maximizing tolerability during treatment of onychomycosis. Both continuous and pulse treatment regimens were found effective, safe and well tolerated (5,6). The total amount of drug administered in the pulse treatment regimen is three times lower than with continuous therapy. Following pulse therapy with itraconazole, the drug has been detected in the distal ends of nail plate in therapeutic concentrations. After the last pulse, the drug remains in the nail plate for several months (5,7).

## PATIENTS AND METHODS

Seventeen patients, males and females, with distolateral subungual onychomycosis, were evaluated in a prospective, open and non-comparative study. In 15 patients onychomycosis was present on toenails and in 2 patients on fingernails. Patients were studied at the Clinical Center, Department of Dermatology in Ljubljana and at the Dermatology Department of Maribor Teaching Hospital.

Inclusion criteria were: patients' age between 18 and 70 years of age, written or verbal informed consent, distolateral subungual onychomycosis, confirmed by direct mycological examination and with positive culture of a dermatophyte, yeast or mould, no previous antifungal therapy (systemic more than 3 months and topical more than two weeks before the study).

Exclusion criteria were: severe onychomycosis with more than 75% of nail surface affected, pregnancy or lactation, any severe underlying disease, psoriasis, diabetes, clinical evidence of peripheral vascular

disease, disease or treatment inducing immunosuppression, history of hepatopathy, concomitant use of drugs with potential interaction with itraconazole (astemizole, terfenadine, digoxin, oral anticoagulants, phenitoin, cyclosporine, etc.).

The therapeutic scheme used was 200 mg itraconazole twice daily (400 mg per day), for the first week of each month, followed by 3 weeks without therapy. Three monthly cycles were given for toenail onychomycosis and 2 monthly cycles for fingernail onychomycosis. Post-treatment follow-up was 10 months for toenail onychomycosis and 8 months for fingernail onychomycosis. The study ended 48 weeks after the start of the therapy.

## Evaluation criteria

Monthly clinical evaluations were performed during treatment (every fourth week) and at week 12, 24 and 36 for fingernail onychomycosis and additionally at week 48 for toenail onychomycosis. After completion of therapy patients with fingernail onychomycosis were followed for 8 months and patients with toenail onychomycosis for 10 months. The length of the unaffected part of the target nails was registered before the start of the treatment and at each subsequent clinical examination. Measurement was longitudinally made from the proximal ungueal edge up to the beginning of the involvement. Clinical response was defined as cured (more than 90% of clear nail), markedly improved (more than 50% clinical improvement), moderately improved (less than 50% clinical improvement), unchanged and deteriorated. Besides, at each clinical assessment signs of onycholysis, hyperkeratosis and paronychia were also evaluated and defined as severe, moderate, mild or absent.

Direct mycological examination and culture in Sabouraud's dextrose agar were performed at baseline,

Table 1. Clinical and mycological efficacy in onychomycosis after three months of pulse therapy with itraconazole.

Efficacy	week 12	week 24	week 36	week 48
clinical efficacy (%)				
cured	5.9	35.3	64.7	73.3
marked improvement	35.3	52.9	35.3	26.4
moderate improvement	58.8	11.8		
unchanged				
deterioration				
mycological cure*	35.3	88.2	82.4	80.0

\*negative microscopy and culture

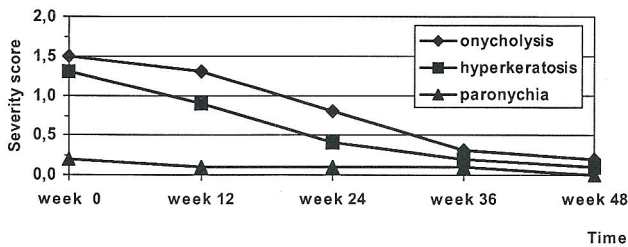


Figure 1. Regression of clinical signs of onychomycosis, onycholysis, hyperkeratosis and paronychia, during the study.

at the end of the pulse therapy treatment and at each patient's visit during post-treatment follow-up.

Laboratory tests including complete hemogram, transaminases, alkaline phosphatase, direct, indirect and total bilirubin, urea, creatinine and total cholesterol were performed at the screening visit.

All adverse events were recorded at each visit during therapy and the follow-up period. Overall tolerability of the medication was rated by patients 1 or 2 months after completion of therapy for fingernail and toenail onychomycosis.

## RESULTS

Of eighteen patients included at the start of the investigation, seventeen completed all the stages of the protocol, seven males, and ten females. Their ages varied from 31 to 69 years (median age 51 years). Duration of onychomycosis ranged from 0,7 to 18 years (mean duration 3.7 years). In two patients onychomycosis was located on fingernails and in 15 patients on toenails. One patient was dropped because he was lost to follow-up.

Dermatophytes were the most prevalent fungus isolated (altogether in 83% of patients), *Trichophyton rubrum* in 53%, *Trichophyton mentagrophytes* in 40% and *Trichophyton verrucosum* in one patient. Dermatophytes were isolated from toenails only. In one patient with toenail onychomycosis *Scopulariopsis*

*brevicaulis* was the isolated pathogen. In the two patients with fingernail onychomycosis *Candida species* were isolated (12%).

## Clinical response

At week 12 marked improvement was present in 41.2% of the patients and in 5.9% clinical cure was established. At the last follow-up visit clinical response was recorded in all patients, 73% of them were considered cured and in 27% marked improvement had been achieved (Table 1).

Median length of unaffected nail parts was increased at every subsequent examination, from 8 mm at baseline visit to 14 mm at the end of the study. This increase was statistically significant ( $p \leq 0.001$ ). In all patients significant improvement of all three clinical signs, onycholysis, hyperkeratosis and paronychia were recorded, both during the treatment and post-treatment period. Severity of onycholysis decreased from 1.5 severity score at the first visit to 0.2 at the final evaluation. Severity of hyperkeratosis has also been decreased during all stages of evaluations, from 1.3 to 0.1 of severity score. Severity of paronychia decreased at every subsequent examination as well (Figure 1).

## Mycological response

At the end of the study 15 out of 17 cultures (88.2%) were negative. In two patients with toenail onychomycosis negative cultures had already been achieved during post-treatment period, but became positive again, in one at week 36 and in another at week 48. *Trichophyton rubrum* developed in both of them. In two patients with fingernail onychomycosis complete clinical and mycological cure was already achieved at week 24.

Overall efficacy with clinical and mycological cure in patients with fingernail and toenail onychomycosis is presented in figure 2.

## Patient tolerance

During the treatment period possibly drug related adverse events occurred in three patients (17%). Two patients reported headache and one patient nausea and diarrhea. These patients experienced the adverse events during the week of drug administration. None of these events were serious and it was not necessary to suspend treatment. Laboratory data were within normal range in all patients at the beginning of the study. During therapy, the patients

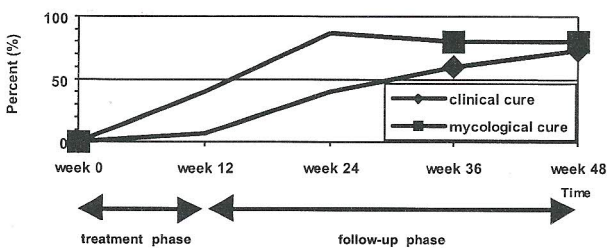


Figure 2. Clinical and mycological cure rates in onychomycosis during and after itraconazole pulse therapy.

showed no evidence of laboratory data deterioration and it was not necessary to repeat them.

## DISCUSSION

The number of patients in our study was rather small, with only two patients presenting onychomycosis due to *Candida spec.* on fingernails. *Trichophyton rubrum* was the most frequent fungus isolated on toenails, followed by *Trichophyton mentagrophytes*, as observed in other countries (5,8). Our results agreed with most of the data found in the literature and confirm that itraconazole is a highly effective drug in the treatment of distolateral toenail onychomycosis, caused by dermatophytes as well as in fingernail onychomycosis due to yeasts.

Two pulses were efficient for fingernail onychomycosis and three pulses for distolateral toenail onychomycosis. In none of our patients severe toenail onychomycosis with nail matrix involvement was present. For more extensive nail involvement additional itraconazole pulses would be necessary (9). After drug discontinuation, an improvement of all clinical signs was observed: the length of unaffected

nail parts, onycholysis, hyperkeratosis and paronychia. At the final evaluation, 8 months after completion of therapy for fingernail and 10 months for toenail onychomycosis, clinical cure rates were 100% and 73%, respectively.

Follow-up lasted several months in our patients allowing detection of possible relapses or reinfections. The data on relapses in toenail onychomycosis are rather contradictory in the literature. In our study in two patients with toenail onychomycosis (13.3%) *Trichophyton rubrum* was cultured once again at the final visit. This was considered a relapse because in both cases complete clinical cure had not been achieved.

## CONCLUSION

Pulse therapy with itraconazole was found safe and well tolerated in our patients. Adverse events occurred in 17% of them (headache, nausea, and diarrhea) but only during the drug ingestion period and did not require drug suspension. Intermittent therapy was also found convenient and was associated with good patient compliance.

## REFERENCES

1. Pierard GE, Arrese-Estrada J, Pierard-Franchimont C. Treatment of onychomycosis: Traditional approaches. *J Am Acad Dermatol* 1993; 29: S41-S45.
2. Roseeuw D, De Doncker P. New approaches to the treatment of onychomycosis. *J Am Acad Dermatol* 1993; 29: S45-S50.
3. Hay RJ. Risk/benefit ratio of modern antifungal therapy: Focus on hepatic reactions. *J Am Acad Dermatol* 1993;29:S50-S54.
4. Denning DW et al. Fungal nail disease: a guide to good practice (report of a Working Group of the British Society for Medical Mycology). *BMJ* 1995; 311: 1277-81.
5. De Doncker P et al. Antifungal Pulse Therapy for Onychomycosis. *A Pharmacokinetic and Pharmacodynamic Investigation of Monthly Cycles of 1-Week Pulse Therapy With Itraconazole*. *Arch Dermatol* 1996; 132: 34-41.
6. Havu V et al. A double blind randomized study comparing itraconazole pulse therapy with continuous dosing for the treatment of toenail onychomycosis. *B J Dermatol* 1997; 136: 230-4.
7. Willemsen M, De Doncker P, Willems J et al. Post-treatment itraconazole levels in the nail. *J Am Acad Dermatol* 1992; 26(5): 731-5.
8. Heikkila H, Stubb S. The prevalence of onychomycosis in Finland. *Br J Dermatol* 1995; 133: 699-703.
9. Ramos-e-Silva M et al. Efficacy and safety of itraconazole pulse therapy: Brazilian multicentric study on toenail onychomycosis caused by dermatophytes. *J Eur Acad Dermatol* 1998; 11: 117-21.

## AUTHORS' ADDRESSES

Ida Prelog, MD, dermatologist, Head Department of Dermatology,  
Teaching Hospital Maribor, 2000 Maribor, Slovenia  
Mateja Dolenc-Voljč, MD, dermatologist, Department of Dermatology, University Medical Center,  
1525 Ljubljana, Slovenia