

Cytokine concentrations in basal cell carcinomas of different histological types and localization

I. Elamin, R. D. Zečević, D. Vojvodić, L. Medenica, and M. D. Pavlović

ABSTRACT

Background: Basal cell carcinoma (BCC) is the most common malignant skin tumor. Cytokines as major mediators of the immune system have been shown to play an important role in biology of the neoplasm with the general predomination of Th2 cytokines, whereas IFN- γ and other Th1 cytokines are prevalent in spontaneously regressing tumors.

Objective: We were interested in comparing cytokine levels in BCC and cutaneous squamous cell tumors with BCC of different localization and histological subtypes.

Material and methods: Explants from freshly excised BCC from 18 patients, and cutaneous squamous cell tumors (solar keratoses and Bowen's disease) from 9 patients were cultivated for 24 h. Cytokine (IL-2, IFN- γ , IL-4, IL-5, IL-6, IL-8, IL-10, IL-12, TNF α , IL-1 β) concentrations in culture supernatants were determined by a sandwich immunoassay.

Results: Tissue explants of BCC contained significantly higher concentrations of IL-1 β , IL-4, IL-5, and IL-6 compared to those of squamous cell tumors. Higher levels of TNF- α ($p = 0.042$), IL-4 ($p = 0.028$), and IL-5 ($p = 0.012$) were found in tumors localized to the head and neck compared to those on the trunk or extremities. Interleukin-6 concentrations were higher in aggressive BCC variants (infiltrative and micronodular), but the difference was not statistically significant ($p = 0.068$).

Conclusions: Confirming the earlier findings that BCC is a tumor with a Th2 cytokine microenvironment, this study further shows that BCC situated on the head and neck produce even more of certain Th2 cytokines (IL-4 and IL-5) and TNF- α , a crucial immunosuppressive cytokine released upon UVB irradiation.

KEY WORDS

basal cell carcinoma, cytokines, localization, aggressive histological subtypes, solar keratosis

Introduction

Basal cell carcinoma (BCC) is the most common malignant tumor in whites and accounts for up to 80% of all malignant skin tumors (1, 2). Some authors put

forward the hypothesis that BCC occurring at certain body sites or BCC of a particular histological subtype may define certain clinical behavior and may even have

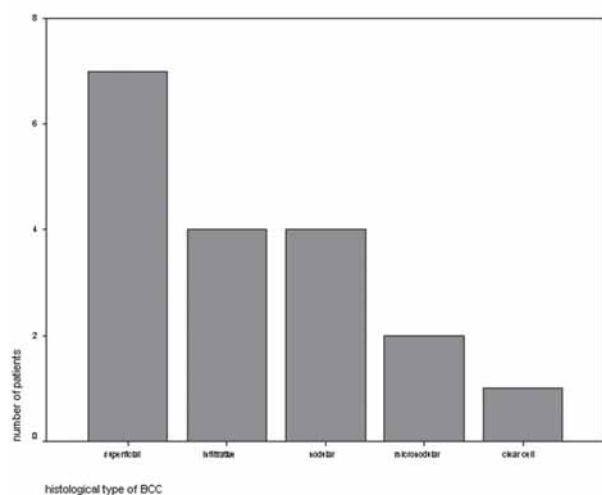


Figure 1. Distribution of histological subtypes of basal cell carcinomas in our patients.

a different etiology (3–5). These studies have shown that the most common histological variety found on the trunk is the superficial type, thus linking this type of BCC with intense intermittent sun exposure. However, a recent Australian study seems to disprove these conclusions, showing a more equal distribution of superficial BCC on face, trunk, and limbs (6). Nevertheless, it is well known that head and neck BCC display a higher propensity for recurrence after treatment compared to tumors located on other body sites (1, 2). It is believed that the presence of hair follicles and the downward spread of the tumor along the follicles makes it less amenable to complete excision, thus increasing the likelihood for recurrence. The immune system has an important role in the biology of BCC (1). Cytokines, crucial players in the system, have been shown to exert important effects on the growth of BCC (7).

We hypothesized that BCCs not only display different cytokine profiles compared to non-BCC skin tumors, but that tumors situated on the head and neck produce more immunosuppressive cytokines, which contribute to their more aggressive biological behavior.

Patients and methods

Upon approval of the Institutional Review Board, 18 successive patients (16 men; mean age 71.9 ± 9.2 years) with dermoscopically and histologically proven, previously untreated basal cell carcinoma were included in the study. The control group was comprised of 9 patients (7 men; mean age 72.7 ± 5.0 years) with histologi-

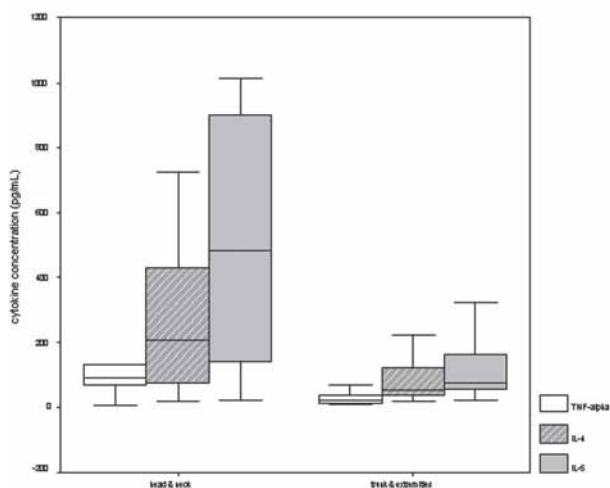


Figure 2. Concentration (mean \pm SD) of TNF- α , IL-4, and IL-5 in BCC of different localizations (head and neck versus trunk and limbs).

cally confirmed, previously untreated squamous cell tumors (solar keratoses and Bowen's disease). The patients signed a written informed consent prior to inclusion in the study. The surgically-excised tumors were immediately halved, and one sample was routinely processed for pathohistology, whereas the other half was cultivated in the medium (5 mL of sterile RPMI, pH 7.4) at 37 °C with 5% CO₂ for 24 h. After 24 h, the culture medium was collected, centrifuged at 2000 \times g for 15 min, and the supernatant aliquoted and kept frozen at -70 °C until cytokine measurements were taken. Cytokines (IL-2, IFN- γ , IL-4, IL-5, IL-6, IL-8, IL-10, IL-12, TNF α , IL-1b) were quantified by the commercial sandwich immunoassay FlowCytomix (Bender MedSystems, Burlingame, CA, USA). The obtained values were calculated per g of tissue and expressed as pg/mL. The results were analyzed with the two-sided Student *t*-tests. The *p* value was set at < 0.05.

Results

The excised tumors in patients and controls were separated into 3 groups according to their localization: trunk, head and neck, and extremities. BCC was localized to the trunk in 7 (39%) patients, to the head and neck in 6 (33%) patients, and to the extremities in 5 (28%) patients. Histologically, the most common form was superficial BCC (7/39), whereas micronodular and clear cell types were found in 2 and 1 patient, respectively (Fig. 1).

Tissue explants of BCC contained significantly higher

Table 1. Mean cytokine concentrations in tissue explants of basal cell carcinomas (Group 1) and squamous cell tumors (Group 2).

Cytokine	Group	n	Mean	SD	p	95% CI
IL-6	1	18	1895.8889	2367.9993	0.024	203.95–2596.48
	2	9	495.6667	353.4134		
IL-8	1	18	284.2778	433.2373	> 0.05	–16.96–419.96
	2	9	82.7778	60.8703		
IL-10	1	18	12.8889	33.7027	> 0.05	–24.42–19.31
	2	9	15.4444	20.9947		
IL-2	1	18	0.2778	1.1785	> 0.05	–331.99–119.88
	2	9	106.3333	293.9349		
IFN- γ	1	18	379.6667	1506.3704	> 0.05	–425.06–1082.17
	2	9	51.1111	139.6159		
IL-12	1	18	58.0000	140.4706	> 0.05	–29.83–118.06
	2	9	13.8889	39.4412		
TNF- α	1	18	72.7222	136.2095	> 0.05	–10.98–125.31
	2	9	15.5556	12.7584		
IL-1 β	1	18	197.8333	205.0111	0.004	57.66–262.89
	2	9	37.5556	19.7301		
IL-5	1	18	253.6667	319.9366	0.012	53.43–373.23
	2	9	40.3333	27.0463		
IL-4	1	18	148.6111	180.2172	0.015	26.03–208.51
	2	9	31.3333	28.6836		

concentrations of IL-1 β , IL-4, IL-5, and IL-6 in comparison to those of squamous cell tumors (Table 1). When cytokine concentrations were analyzed in BCC located in different sites, we found higher levels of TNF- α ($p = 0.042$), IL-4 ($p = 0.028$), and IL-5 ($p = 0.012$) in tumors localized to the head and neck comparing to those on the trunk or extremities (Fig. 2). Then we compared cytokine concentrations in aggressive (micronodular and infiltrative) and non-aggressive (superficial and nodular) histologic types of BCC. There was no any significant difference in the cytokine levels. However, IL-6 concentrations were higher in aggressive BCC variants, although the difference did not reach statistical significance ($p = 0.068$).

In addition, histologic subtypes of BCC did not differ with respect to cytokine concentrations in their tissue explants (not shown).

Comment

Basal cell carcinoma, under certain circumstances, undergoes spontaneous regression that is probably mediated by the immune system (7, 8). Islands of tumor cells are surrounded by regulatory CD4⁺, CD25⁺, Foxp3⁺ T (Treg) lymphocytes, and numerous immature dendritic cells. The microenvironment of BCC is dominated by

Th2 cytokines (enhanced expression of IL-4, IL-10, and CCL22). A partial anti-tumor response is marked by the presence of CD8⁺ T cells and the activation of interferon and IL-12/23 genes (8). Gambichler et al. (9) have found higher levels of mRNA for IL-6 and IL-8 in the tissue of BCC in comparison to uninvolved skin or the skin of individuals without BCC ($p < 0.05$). It has been shown that IL-6 via basic fibroblast growth factor (bFGF) and cyclooxygenase 2 (COX-2) promotes angiogenesis in BCC (10). In addition, IL-6 enhances tumorigenic potential and anti-apoptotic activity in human BCC (11). Our findings are in line with the predominance of Th2 cytokines (IL-4, IL-5, IL-6) and IL-1 β in BCC in comparison with solar keratoses and Bowen's disease (Table 1). IL-1 β is produced by keratinocytes irradiated by ultraviolet (UV) light (12). A previous study on a BCC cell line has shown that it produced less IL-1 β than normal keratinocytes (13). However, our results were obtained from freshly excised tumor tissue and thus may be more relevant for the in vivo situation. Together, it seems that microenvironment of BCC compared to healthy skin or squamous cell tumors displays a strong predominance of Th2 cytokines or, in other words, a specific state of immunosuppression.

We have found that BCC situated on the head and neck express more Th2 cytokines (IL-4 and IL-5) and tumor necrosis factor (TNF)- α than tumors on the

trunk and limbs (Fig. 2). Hence, the higher level of immunosuppression in tumors at these sites may be an additional explanation for their more aggressive biological behavior. It is known that TNF- α plays a central role in immunosuppression induced by UVB (14). Some authors have shown a higher incidence of polymorphism in the promoter region of the TNF- α gene or a higher secretion of the cytokine from stimulated peripheral blood mononuclear cells in patients with BCC (15, 16).

We did not find significant differences in cytokine concentrations in BCC of various histological subtypes.

Although the IL-6 levels were higher in more aggressive varieties, they were not statistically significant. Even so, this finding is in line with the notable tumorigenic effects of the cytokine (11).

The differences in cytokine expression confirm the earlier conclusions that BCC is a tumor with a Th2 cytokine microenvironment. This study extends the findings showing that BCC situated on the head and neck produce even more of certain Th2 cytokines (IL-4 and IL-5) and TNF- α , a crucial immunosuppressive cytokine released upon UVB irradiation. These data may offer further explanation for the higher recurrence rate of BCC at this site.

REFERENCES

1. Crowson AN. Basal cell carcinoma: Biology, morphology and clinical implications. *Modern Pathology*. 2006;19:127–47.
2. Lear W, Dahlke E, Murray CA. Basal cell carcinoma: review of epidemiology, pathogenesis, and associated risk factors. *J Cutan Med Surg*. 2007;11:19–30.
3. Bastiaens MT, Hoefnagel JJ, Bruijn JA et al. Differences in age, site distribution, and sex between nodular and superficial basal cell carcinomas indicate different types of tumors. *J Invest Dermatol*. 1998;110:880–4.
4. McCormack CJ, Kelly JW, Dorevitch AP. Differences in age and body site distribution of the histological subtypes of basal cell carcinoma. A possible indicator of differing causes. *Arch Dermatol*. 1997;133:593–6.
5. Scrivener Y, Grosshans E, Cribier B. Variations of basal cell carcinomas according to gender, age, location and histopathological subtype. *Br J Dermatol*. 2002;147:41–7.
6. Raasch BA, Buettner PG, Grabe C. Basal cell carcinoma: histological classification and body-site distribution. *Br J Dermatol*. 2006;155:401–7.
7. Wong DA, Bishop GA, Lowes MA, Cooke B, Barnetson RS, Halliday GM. Cytokine profiles in spontaneously regressing basal cell carcinomas. *Br J Dermatol*. 2000;143:91–8.
8. Kaporis HG, Guttman-Yassky E, Lowes MA, Haider AS, Fuentes-Duculan J, Darabi K et al. Human basal cell carcinoma is associated with Foxp3(+) T cells in a Th2 dominant microenvironment. *J Invest Dermatol*. 2007 May 17; [Epub before printing].
9. Gambichler T, Skrygan M, Hyun J, Bechara F, Tomi NS, Altmeyer P, Kreuter A. Cytokine mRNA expression in basal cell carcinoma. *Arch Dermatol Res*. 2006;298:139–41.
10. Jee SH, Chu CY, Chiu HC, Huang YL, Tsai WL, Liao YH, Kuo ML. Interleukin-6 induced basic fibroblast growth factor-dependent angiogenesis in basal cell carcinoma cell line via JAK/STAT3 and PI3-kinase/Akt pathways. *J Invest Dermatol*. 2004;123:1169–75.
11. Jee SH, Shen SC, Chiu HC, Tsai WL, Kuo ML. Overexpression of interleukin-6 in human basal cell carcinoma cell lines increases anti-apoptotic activity and tumorigenic potency. *Oncogene*. 2001;20:198–208.
12. Feldmeyer L, Keller M, Niklaus G, Hohl D, Werner S, Beer HD. The inflammasome mediates UVB-induced activation and secretion of interleukin-1beta by keratinocytes. *Curr Biol*. 2007;17:1140–5.
13. Yen HT, Chiang LC, Wen KH, Tsai CC, Yu CL, Yu HS. The expression of cytokines by an established basal cell carcinoma cell line (BCC-1/KMC) compared with cultured normal keratinocytes. *Arch Dermatol Res*. 1996; 288:157–61.
14. Garssen J, Vandebriel RJ, van Loveren H. Molecular aspects of UVB-induced immunosuppression. *Arch Toxicol Suppl*. 1997;19:97–109.

15. Ramachandran S, Fryer AA, Lovatt TJ, Smith AG, Lear JT, Jones PW, Strange RC. Combined effects of gender, skin type and polymorphic genes on clinical phenotype: use of rate of increase in numbers of basal cell carcinomas as a model system. *Cancer Lett.* 2003;189: 175–81.
16. Skov L, Allen MH, Bang B, Francis D, Barker JN, Baadsgaard O. Basal cell carcinoma is associated with high TNF-alpha release but not with TNF-alpha polymorphism at position "308. *Exp Dermatol.* 2003;12:772–6.

A U T H O R S ' A D D R E S S E S *Issa Elamin, MD, Department of Dermatovenereology, Military Medical Academy, Crnotravska 17, 11002 Belgrade, Serbia*
Radoš D. Zečević, MD, PhD, Professor of Dermatovenereology, same address
Danilo Vojvodić, MD, PhD, Associated Professor of Clinical Immunology, Institute of Medical Research, Military Medical Academy, Crnotravska 17, 11002 Belgrade, Serbia
Ljiljana Medenica, MD, PhD, Professor of Dermatovenereology, Institute of Dermatovenereology, Clinical Center of Serbia, Pasterova 2, 11000 Belgrade, Serbia
Miloš D. Pavlović, MD, PhD, Professor of Dermatovenereology, Department of Dermatology and Venereology, University Medical Center Ljubljana, Zaloška 2, SI-1525 Ljubljana, Slovenia, E-mail: mdpavlovic2004@yahoo.com