

Amelanotic malignant melanoma in an acral location

L. Matusiak, A. Bieniek, Z. Wozniak, and J. C. Szepietowski

S U M M A R Y

We present the case of a 74-year-old white female admitted to the Department of Dermatology because of a tumor in the IV-V interdigital area of her right foot. A crimson, dome-shaped tumor with a granular, spongy surface (diameter 4 cm) had developed over a period of about 3 months. The biopsy, stained with H and E, revealed an anaplastic malignant tumor. Additional immunochemical staining with Melan A allowed us to make the final diagnosis: amelanotic malignant melanoma (MM). The melanoma was removed by amputation of digits IV and V, with partial removal of the metatarsal bones (Clark degree 5, Breslow thickness 9 mm). Sentinel node biopsy was done using Tc^{99m}; it revealed no neoplastic alteration. The patient is still under oncological observation.

Introduction

Approximately 160,000 people (79,000 males and 81,000 females) worldwide were diagnosed with melanoma in 2002, of which about 80% occurred predominantly in Caucasians. On a global scale, malignant melanoma (MM) was the 16th (in males) and the 15th (in females) most commonly diagnosed cancer. About one quarter of people affected with MM worldwide died of the disease (1).

Melanomas located on unusual areas are detected early less frequently. Acral melanomas are often misdiagnosed compared to other anatomic sites (2). The misdiagnosis and delay in diagnosis are statistically associated with a poor prognosis. It is notable that about half

of the incorrect diagnoses concerned amelanotic MM. Frequent misdiagnoses include a wart, callus, fungal disorder, foreign body granuloma, crusted lesion, sweat gland infection, blister, non-healing wound, mole, keratoacanthoma, subungual hematoma, onychomycosis, or ingrown toenail (2, 3).

Case report

A 74-year-old white female was admitted to our department due to a tumor of the IV-V interdigital area of the right foot. A crimson, dome-shaped tumor with a

K E Y W O R D S

**amelanotic,
acral,
melanoma,
ALM,
immuno-
histochemistry,
S-100 protein,
Melan A,
HMB-45**

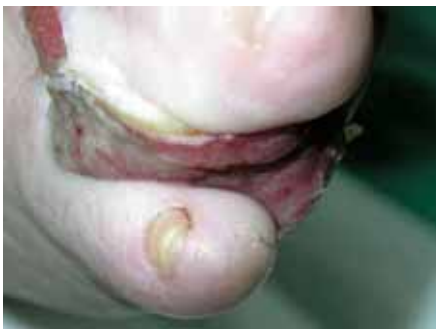

Figure 1.
The tumor;
description
in the text.

granular, spongy surface and a barely visible ulceration had grown in about 3 months. On admission, the diameter of the tumor was 4 cm (Fig. 1.). The surrounding epidermis showed slight maceration. The peripheral lymph nodes were not enlarged. There was no weight loss during the previous 3 months. An undifferentiated, atypical squamous cell carcinoma was first diagnosed.

Biopsies were taken from three sites for histopathological examination. The standard hematoxylin and eosin stain showed an anaplastic malignant tumor with partially necrotic areas of tissue and an ulcerated surface. There were nests of cells with expressed atypia: anisocytosis, anisonucleosis, and heterochromasia, often with big "predominating" nucleoli. The remaining fusiform or dendritic cells were mostly oval with a more or less bright cytoplasm. No brown pigment was observed in the cytoplasm of the tumor cells. The mitotic rate was below 1 mitosis in a high-power field (final zoom at 400 \times) (Fig. 2). Additional positive staining with Melan A (MART-1) and negative EMA and Ck-19 allowed us to make the diagnosis of amelanotic MM (Fig. 3).

Routine laboratory examinations revealed no sig-

nificant abnormalities. Erythrocytes, white blood cells and blood platelet count, blood smear, blood coagulation, urine examination, serum glucose level, electrolytes, and liver tests and kidney function tests were within the normal range or negative. X-ray examination of the chest showed no significant abnormalities. Ultrasonography of the abdomen revealed no changes to the pancreas, kidneys, or urinary tract or vessels, except for steatosis of the liver. There were no enlarged lymph nodes.

The MM was removed by the amputation of digits IV and V and a partial ablation of the metatarsal bones. The post-operative histology confirmed the total excision of the tumor. The diagnosis was nodular MM with ulceration and a predominance of epithelioid-type cells. The tumor thickness was 9 mm, corresponding to level T4 of the Breslow scale. The infiltration reached into subcutaneous tissue, confirming Clark Level V. A few days after the surgery, a sentinel node biopsy was carried out. Using the Tc⁹⁹ isotope and a gamma camera, the right inguinal sentinel node was excised. The histology revealed no neoplastic cells. The postoperative wound healed without complications. The patient still remains under oncological observation.

Discussion

Acral melanoma encompasses all the major clinicopathological subtypes of melanoma, including the nodular type, whose frequency in the location discussed is assessed at 15% (4–8). The development of malignant melanoma in acral areas is not frequent in Caucasians. In a study by Kuchelmeister et al. (9) approximately 7% of patients with cutaneous melanoma had tumors lo-

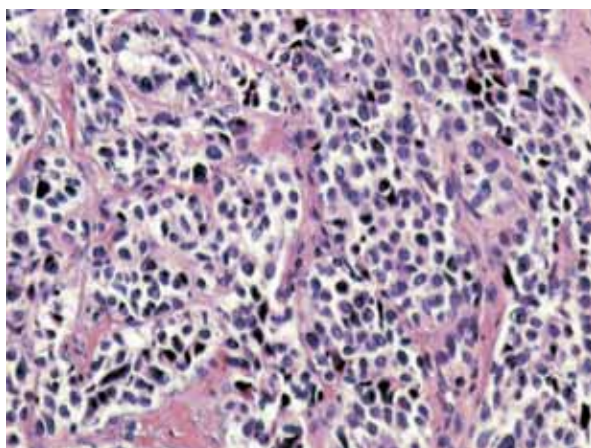


Figure 2. Amelanotic malignant melanoma (typical stain with hematoxylin and eosin); a. HE 100 \times , b. HE 200 \times , c. HE 400 \times ; description in the text

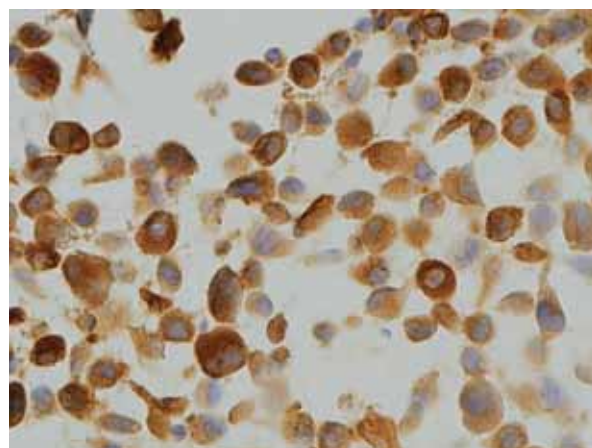


Figure 3. Amelanotic malignant melanoma (Melan A (syn. MART-1)) 400 \times ; highly visible positive reaction for this immunohistochemical stain; description in the text.

cated on acral sites. Acral melanoma is a more common type of melanoma in darker-skinned people (10, 11).

The frequency of amelanotic MM is assessed at less than 10% of all MM cases (12–14). It is noteworthy that almost all non-pigmented melanomas presented as ulcerated nodules, of nodular type or acral-lentiginous MM with a nodular component (8). Such findings, as well as our case, strongly suggest that the vertical growth occurring in plantar melanoma may inhibit the melanin synthesis. The ulceration may result from the rapid tu-

mor growth, provoking the excessive proliferation of immature cells (1, 12).

In cases with atypical histopathology it may be difficult to differentiate amelanotic MM from other immature tumors. In such cases immunohistochemistry should be applied: S-100 protein, Melan A, and HMB-45 (1), as in our case.

In conclusion, a case of amelanotic MM that caused diagnostic difficulties is presented. We point to immunohistochemistry as the decisive examination.

REFERENCES

1. LeBoit PE, Burg G, Weedon D, Sarasin A, editors. World Health Organization classification of tumours. In: Pathology and genetics of tumours of the skin. Lyon: IARC Press; 2006. p. 49–118.
2. Soon SL, Solomon AR Jr, Papadopoulos D, Murray DR, McAlpine B, Washington CV. Acral lentiginous melanoma mimicking benign disease: the Emory experience. *J Am Acad Dermatol.* 2003;48:183–8.
3. Richard MA, Grob JJ, Avril MF, Delaunay M, Gouvenet J, Wolkenstein P, et al. Delays in diagnosis and melanoma prognosis (II): the role of doctors. *Int J Cancer.* 2000;89:280–5.
4. Hudson DA, Krige JEJ, Stunnings H. Plantar melanoma: results of treatment in three population groups. *Surgery.* 1998;124:877–82.
5. Metzger S, Ellwanger U, Stroebel W, Schiebel U, Rassner G, Fierlbeck G. Extent and consequences of physician delay in the diagnosis of acral melanoma. *Melanoma Res.* 1998;8:181–6.
6. Reed RJ. Acral lentiginous melanoma. In: Hartmann W, Kay S, Reed RJ, editors. New concepts in surgical pathology of skin. New York: John Wiley & Sons; 1976. p. 89–90.
7. Kato T, Suetake T, Tabata N, Takahashi K, Tagami H. Epidemiology and prognosis of plantar melanoma in 62 Japanese patients over a 28-year period. *Int J Dermatol.* 1999;38:515–9.
8. Kato T, Tabata N, Suetake T, Tagami H. Non-pigmented nodular plantar melanoma in 12 Japanese patients. *Br J Dermatol.* 1997;136:207–11.
9. Kuchelmeister C, Schaumburg-Lever G, Garbe C. Acral cutaneous melanoma in Caucasians: clinical features, histopathology and prognosis in 112 patients. *Br J Dermatol.* 2000;143:275–80.
10. Kim YC, Lee MG, Choe SW, Lee MC, Chung HG, Cho SH. Acral lentiginous melanoma: an immunohistochemical study of 20 cases. *Int J Dermatol.* 2003;42:123–9.
11. Ishihara K. Questionnaire on malignant melanoma in Japan in the period 1987–1991. *Skin Cancer.* 1994;9:52–68.
12. Huvos AG, Shah JP, Goldsmith HS. A clinicopathologic study of amelanotic melanoma. *Surg Gynecol Obstet.* 1972;135:917–20.
13. Nakleh RE, Wick MR, Rocamora A, Swanson PE, Dehner LP. Morphologic diversity in malignant melanomas. *Am J Clin Pathol.* 1990;93:731–40.
14. Andersen WK, Silvers DN. "Melanoma? It can't be melanoma!" A subset of melanomas that defies clinical recognition. *JAMA.* 1991;266:3463–5.

AUTHORS' ADDRESSES

Lukasz Matusiak, MD, Department of Dermatology, Venereology and Allergology, Medical University, Chalubinskiego 1, 50-368 Wrocław, Poland. E-mail: luke71@interia.pl

Andrzej Bieniek, MD, PhD, same address

Zdzisław Wozniak, MD, PhD, Department of Pathological Anatomy, Medical University, Marcinkowskiego 1, 50-368 Wrocław, Poland

Jacek Cezary Szepietowski, MD, PhD, professor of dermatology, Department of Dermatology, Venereology and Allergology, Medical University, Chalubinskiego 1, 50-368 Wrocław, Poland

Ludwik Hirszfild Institute of Immunology and Experimental Therapy, Polish Academy of Sciences, R. Weigla 12, 53-114 Wrocław, Poland